

Alcohol ablation of ventricular arrhythmias

Miguel Valderrábano

Methodist DeBakey Heart and Vascular Center

Division of Cardiac Electrophysiology

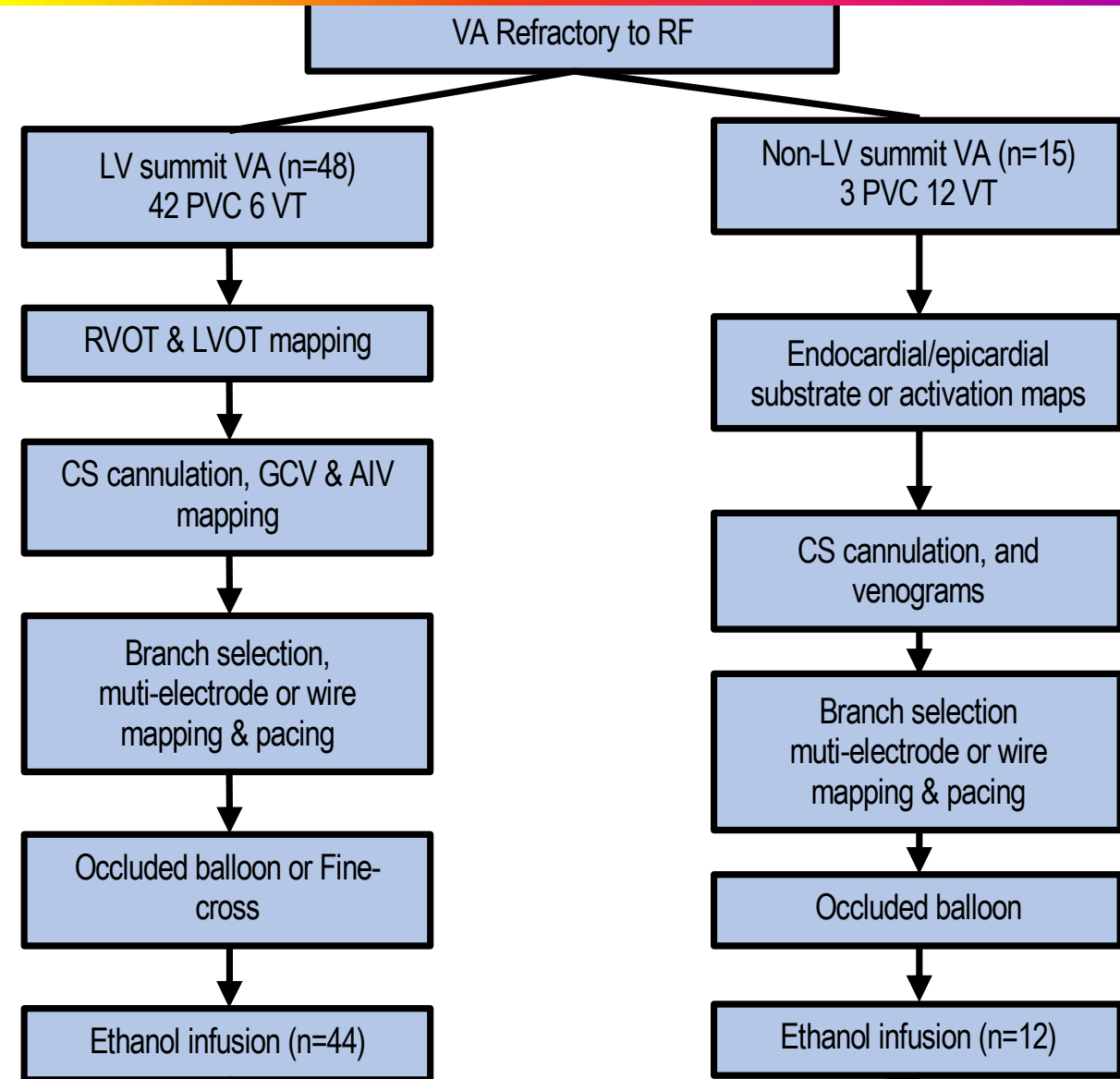
Department of Cardiology

Houston Methodist Hospital

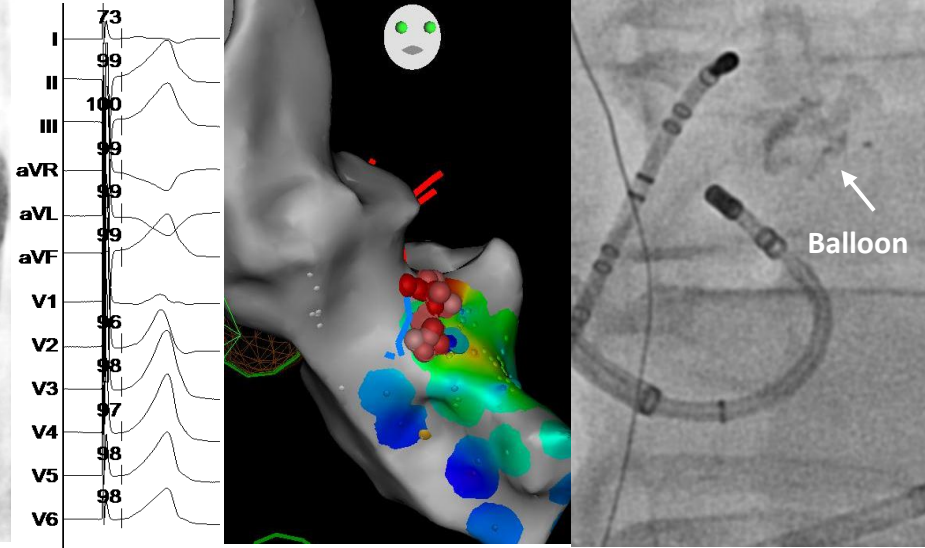
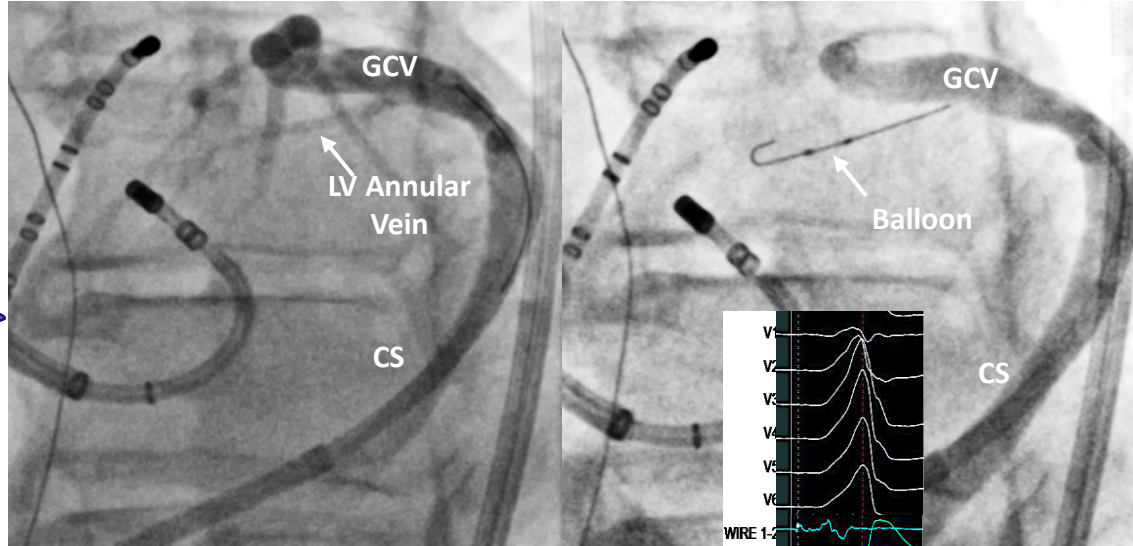
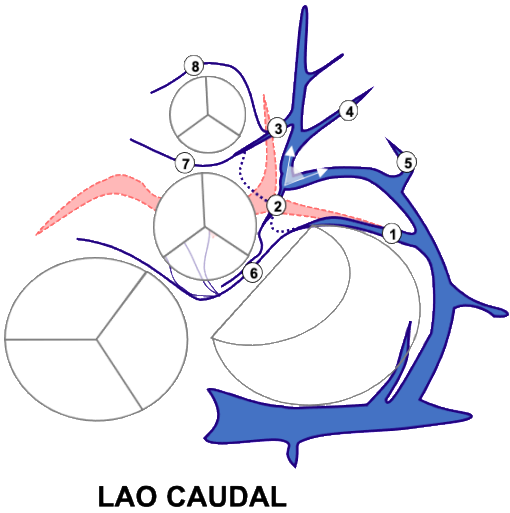
Venous ethanol ablation experience

Tavares et al. *JACC Clin Electrophysiol.* 2020 Oct 26;6(11):1420-1431

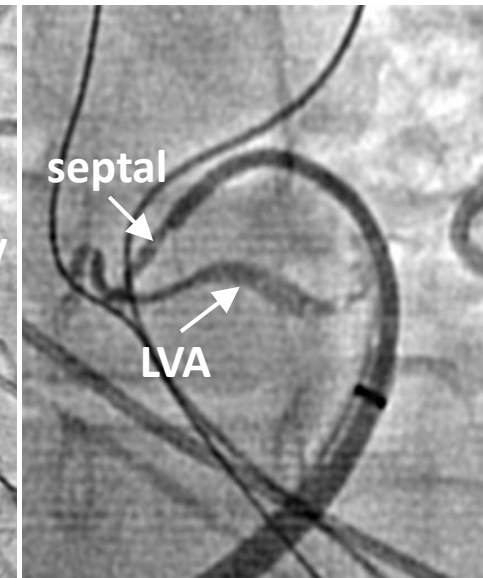
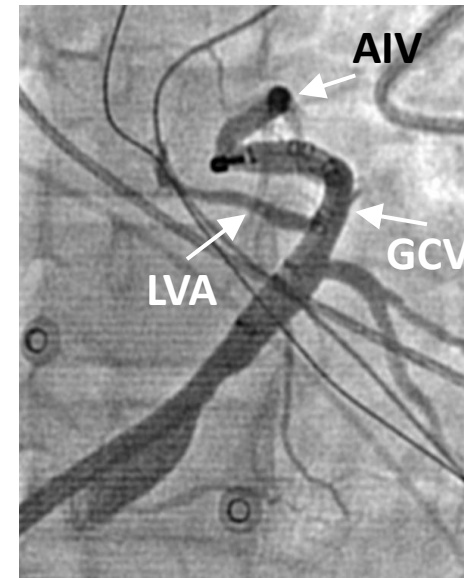
- 12 centers
- 63 patients with ablation-refractory ventricular arrhythmias (PVC & VT).
 - LV summit (n=48)
 - Other regions (n=15)
- Approach:
 - Mapping endo RV/LV/epi
 - CS cannulation, venograms, epicardial vein mapping
 - Intramural branch selection
 - Wire mapping
 - Ethanol delivery



LV summit PVCs: LV annular vein

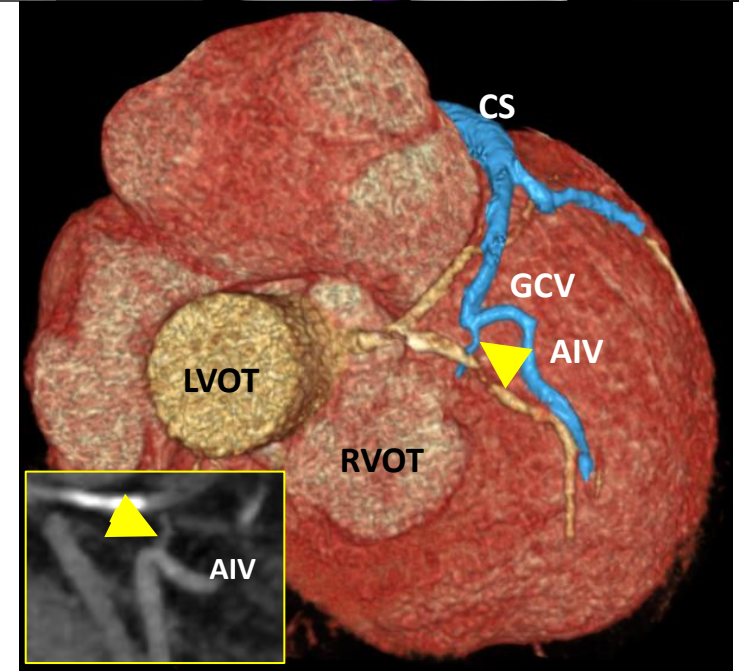
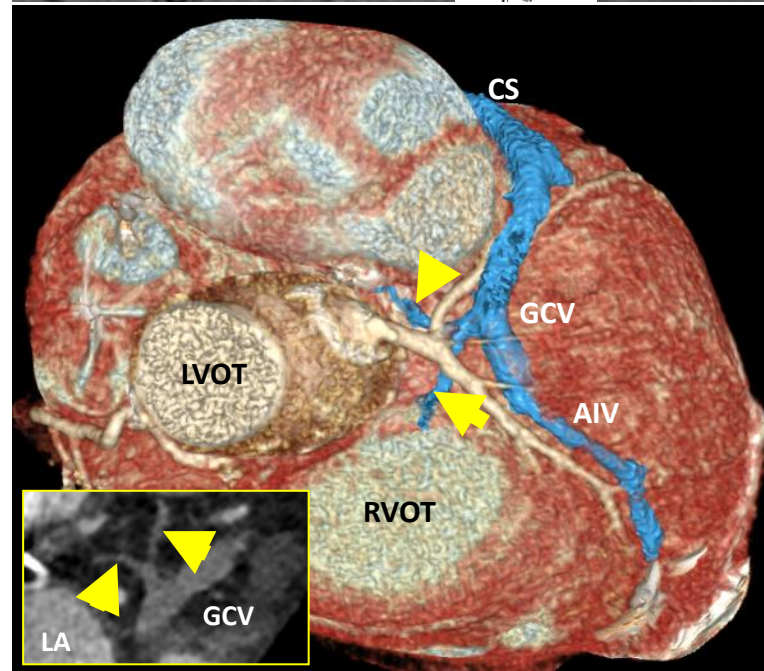
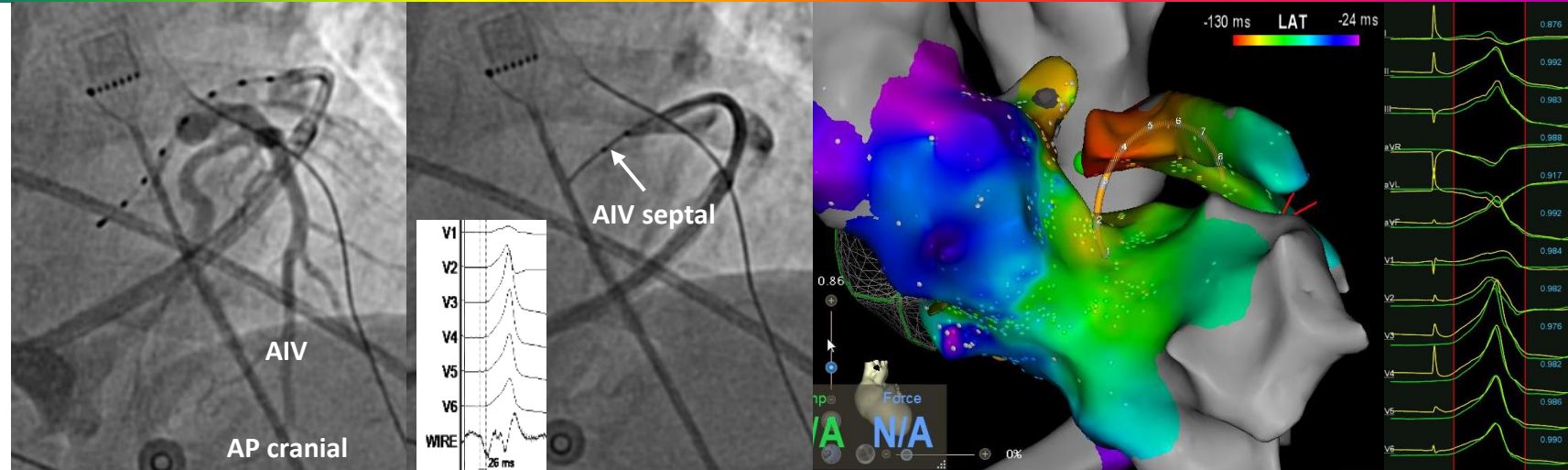


- Present in ~40% of cases
- 5/48 LV summit VT ablated from LV annular with ethanol
- Take-off from GCV
- Atrial and ventricular signals
- May have atrial/retroartiac branches
- May communicate with AIV septal

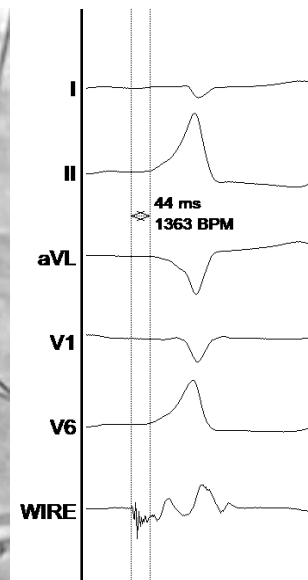
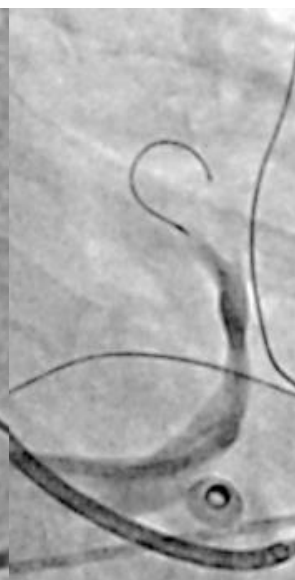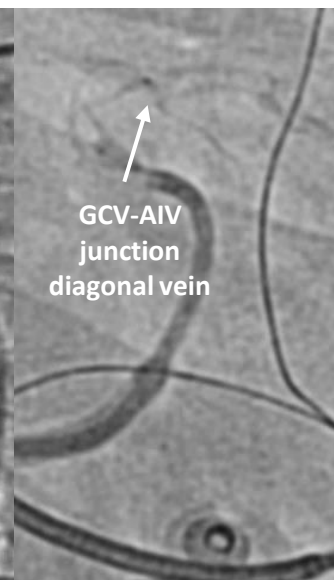
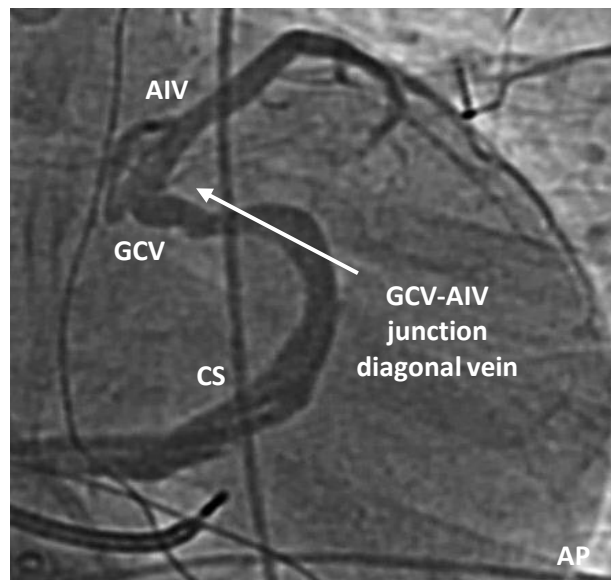
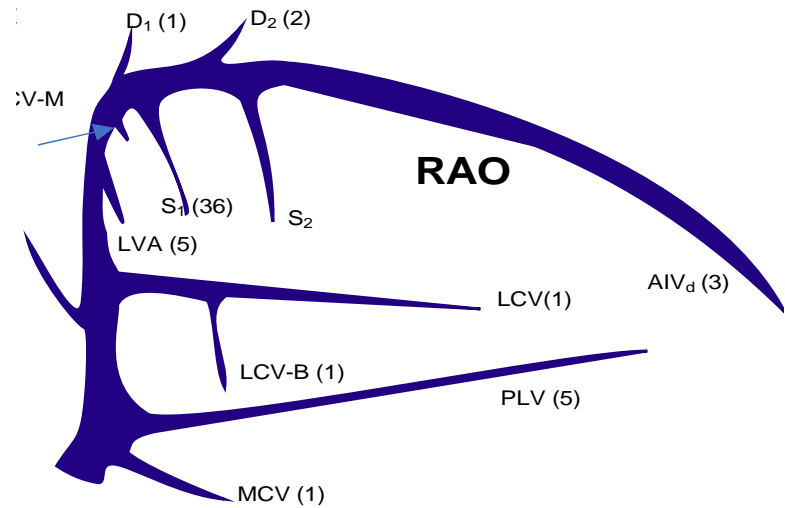
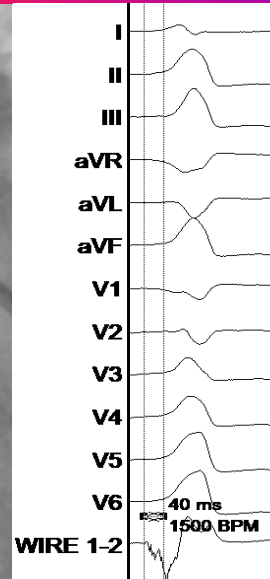
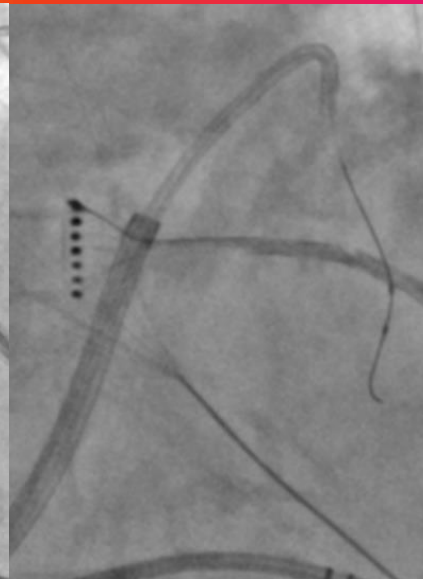
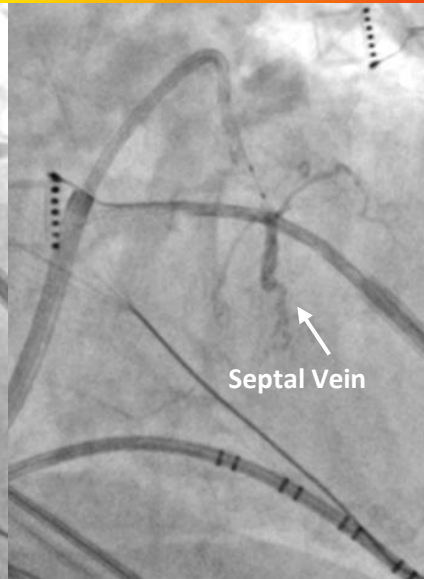
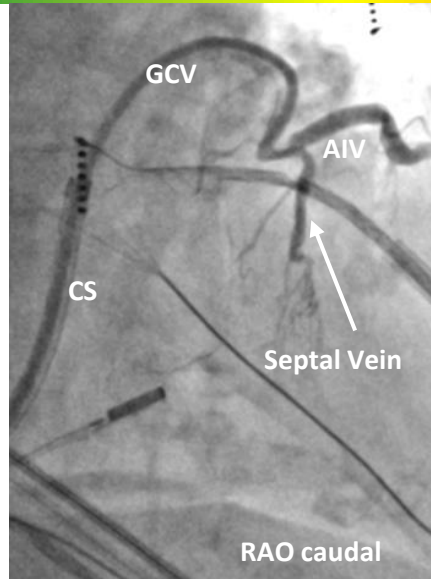
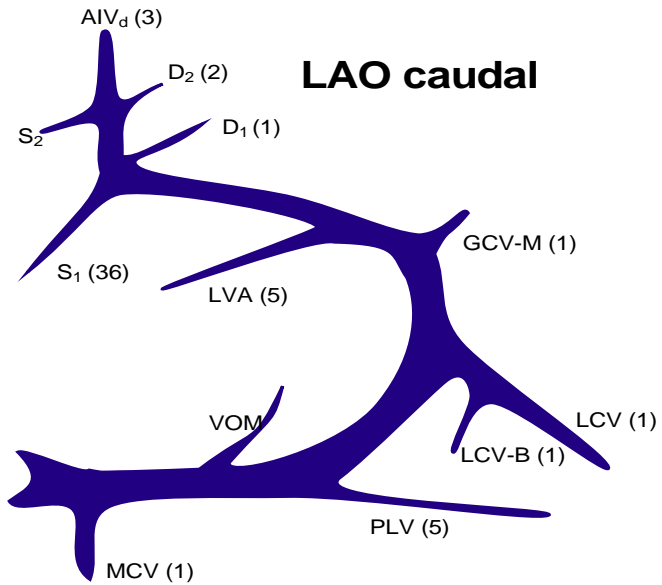


LV summit PVCs: GCV-AIV septals

- Take-off from GCV-AIV angle
- Close to left main artery
- Retro aortic branches
- Retro-pulmonary artery branches
- Most common vein targeted (36/48).

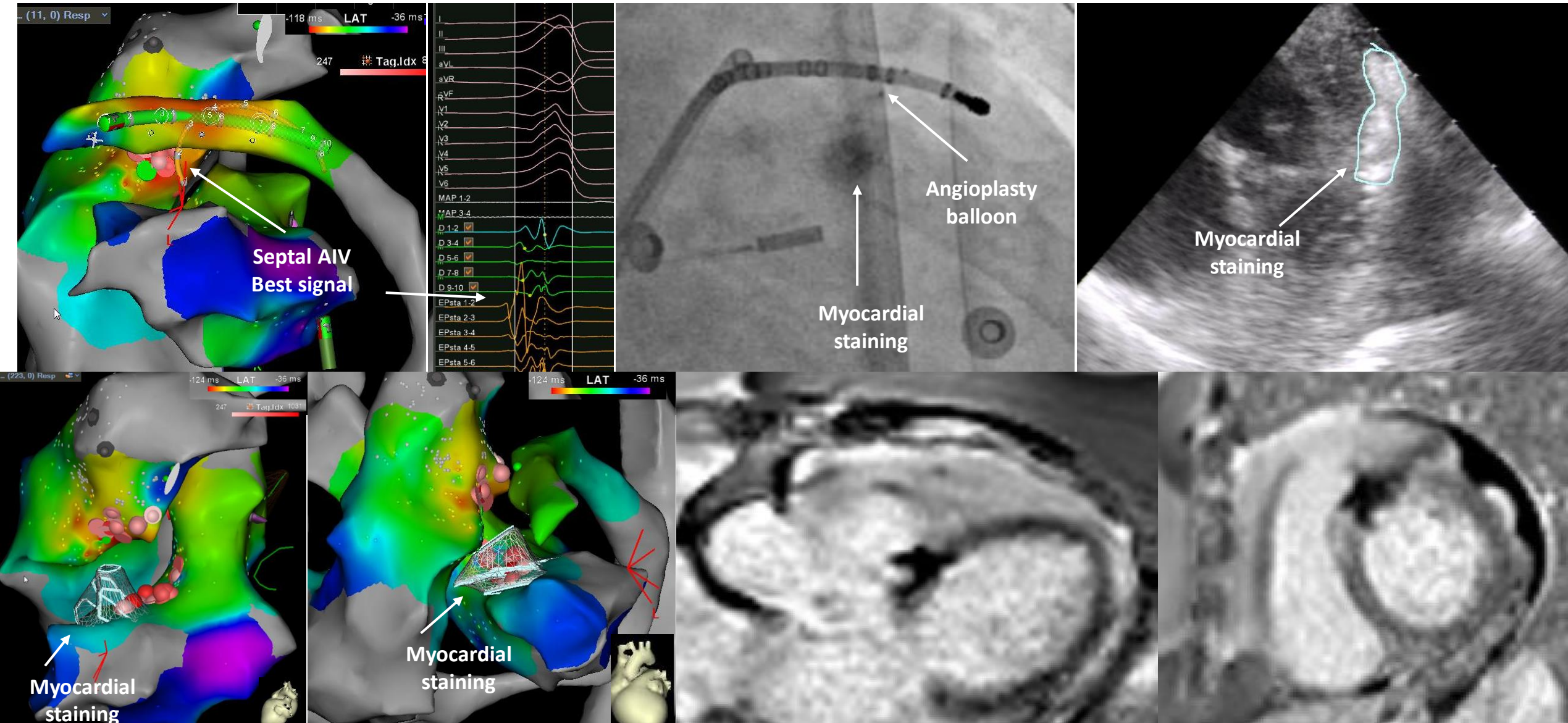


LV summit PVCs: AIV septal & diagonal



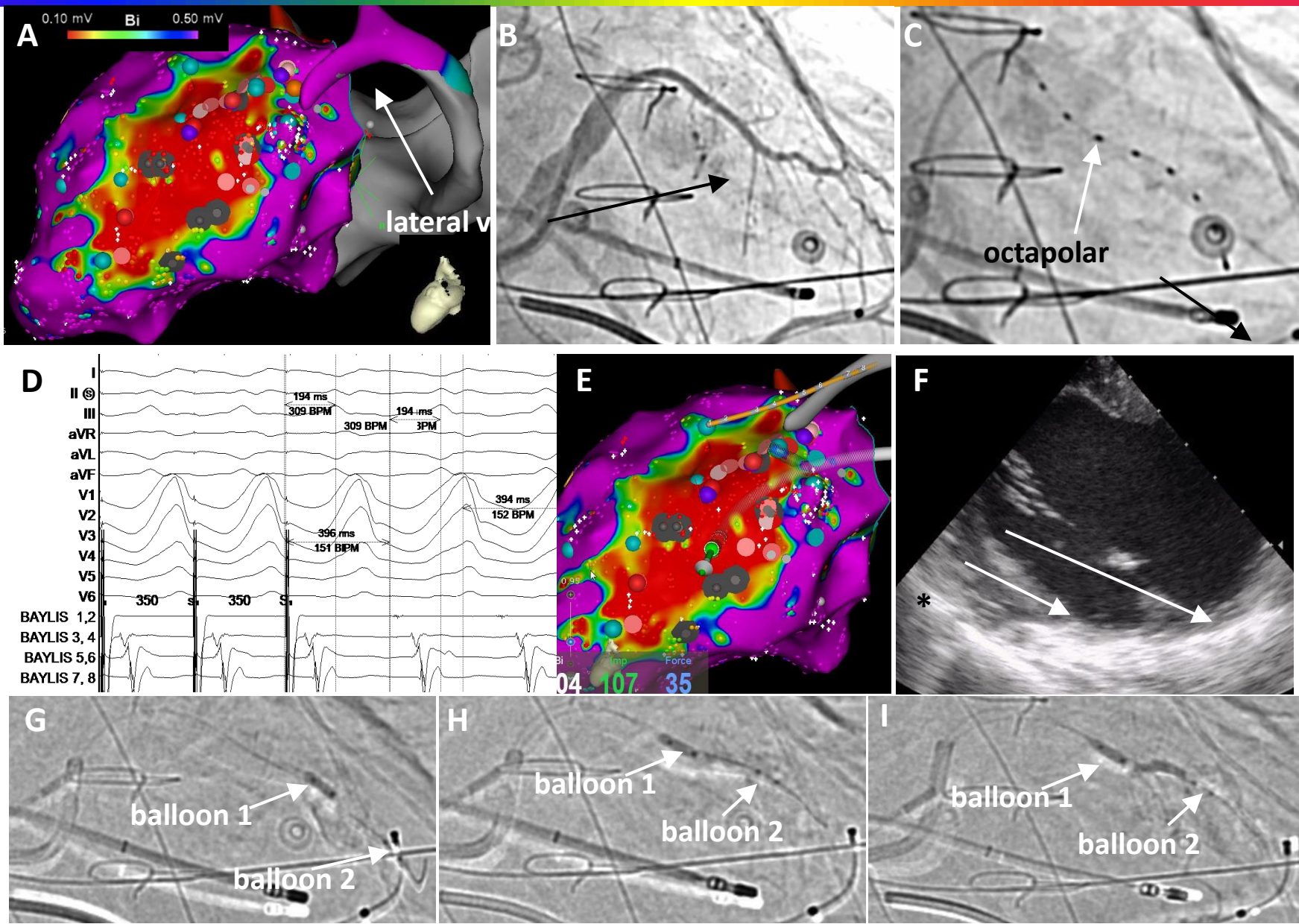
Ethanol-induced intramural ablation

Microvascular obstruction on CMR

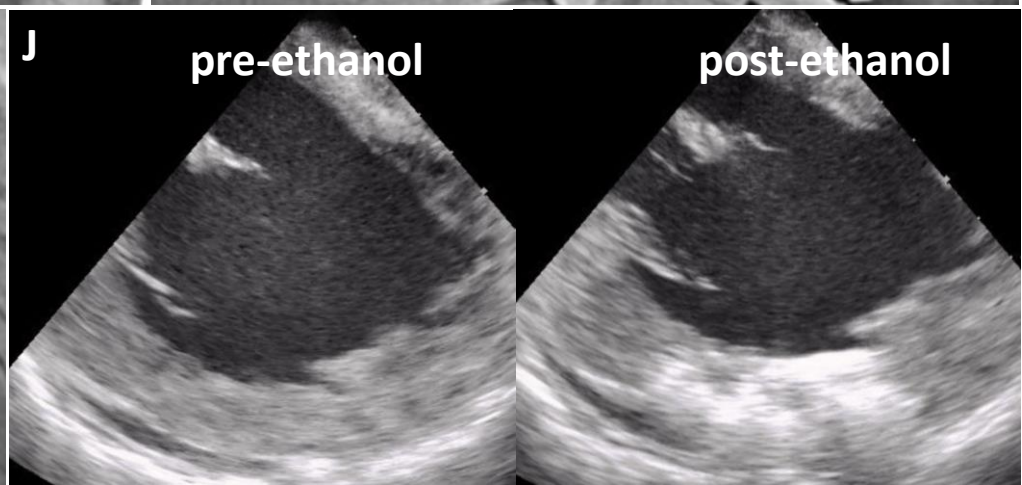
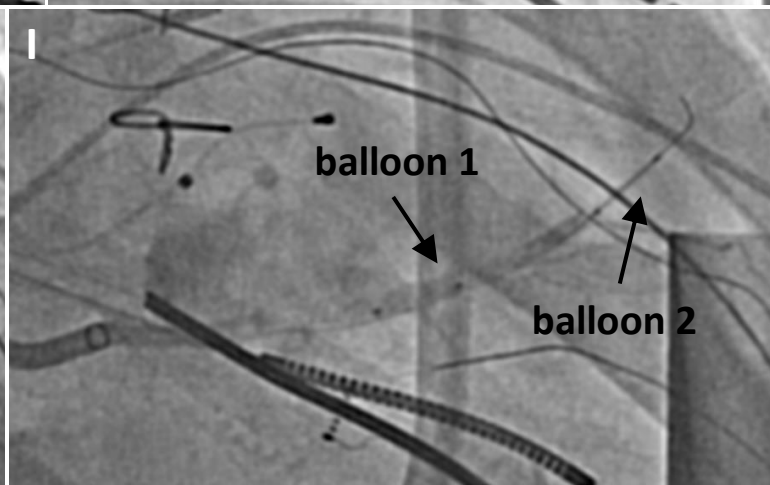
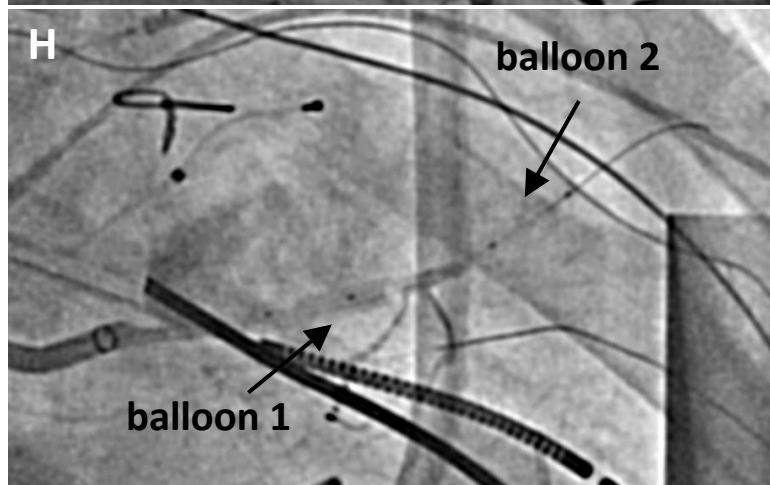
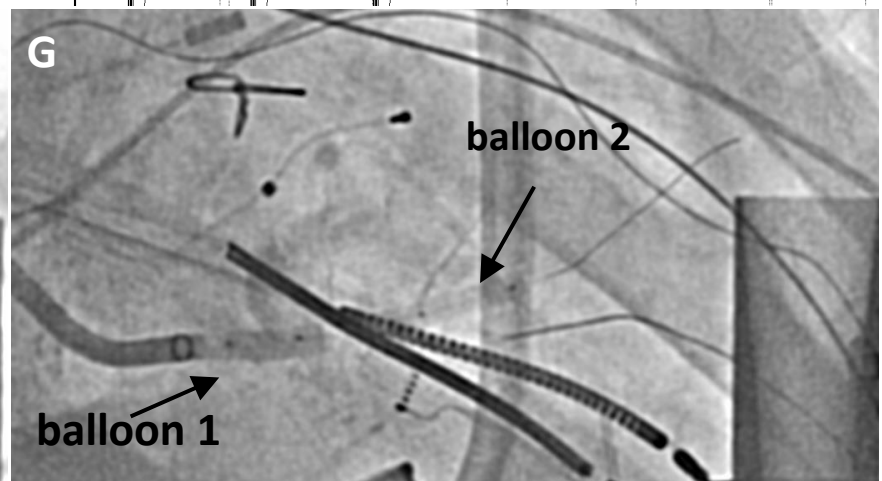
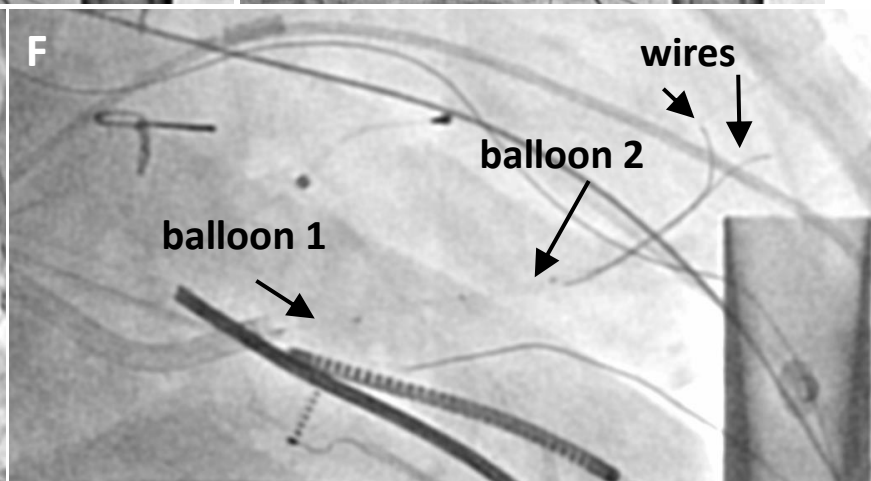
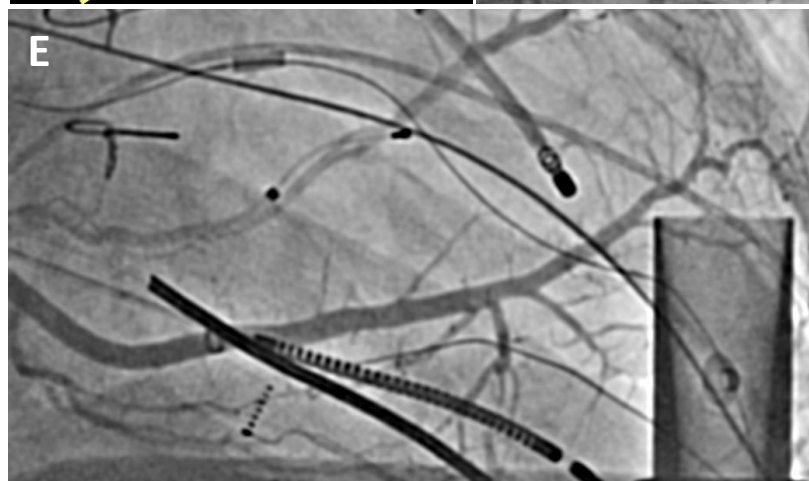
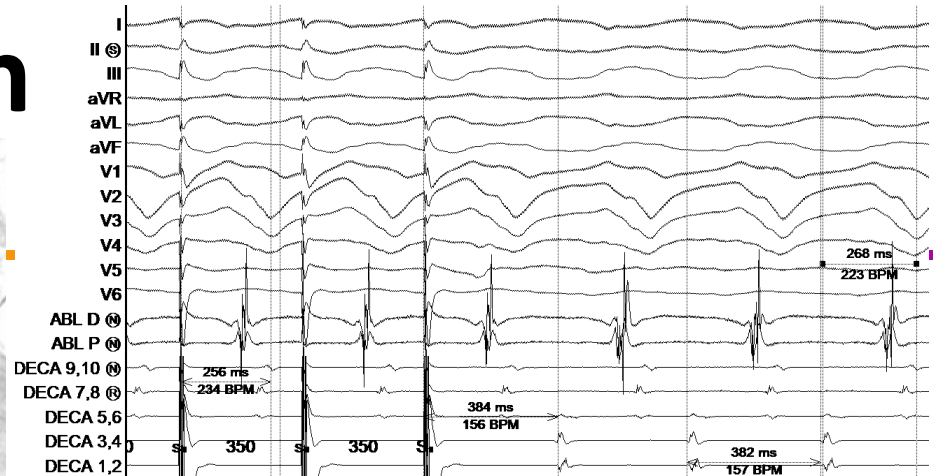

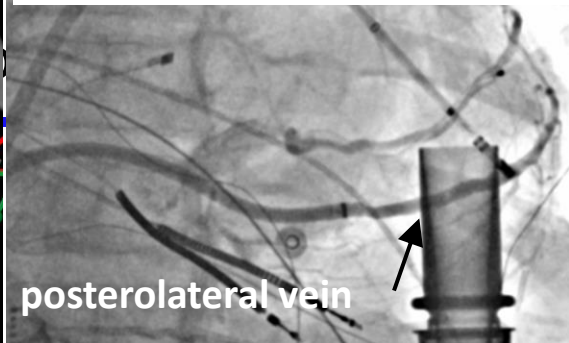
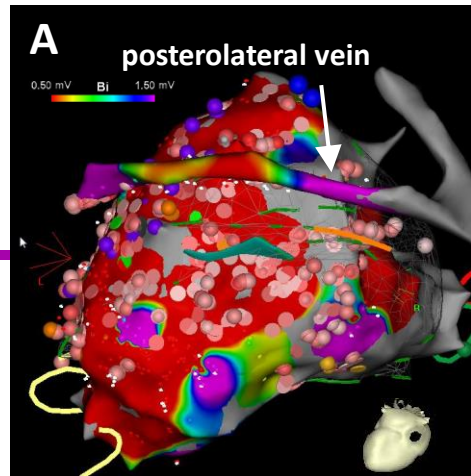


Lateral vein in ischemic VT: Double balloon

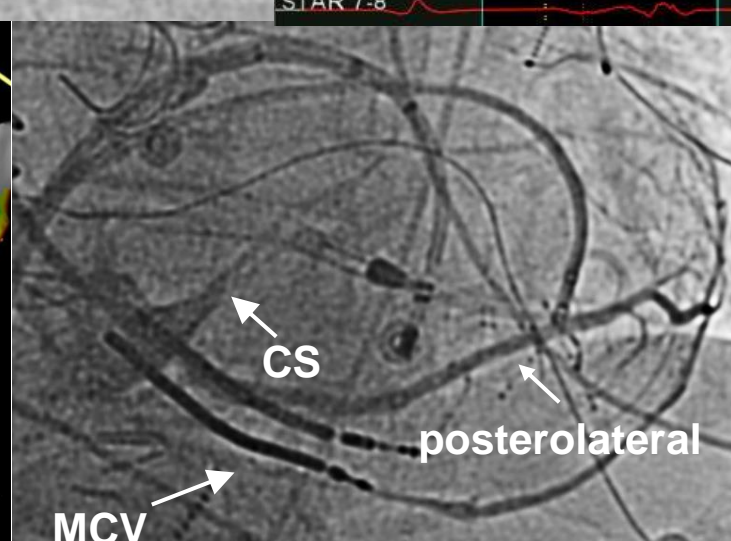
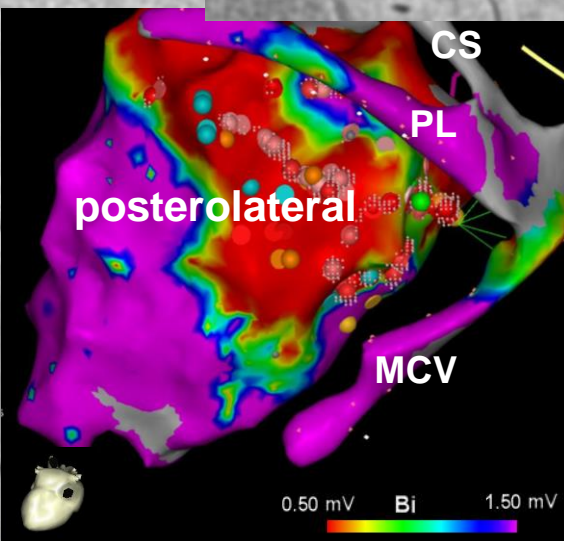
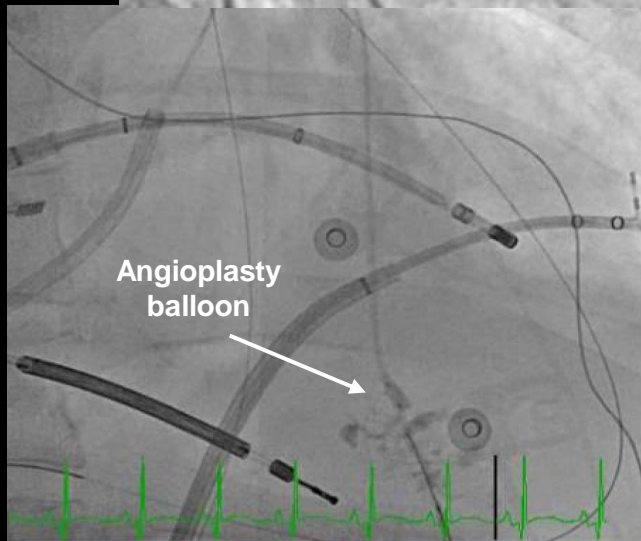
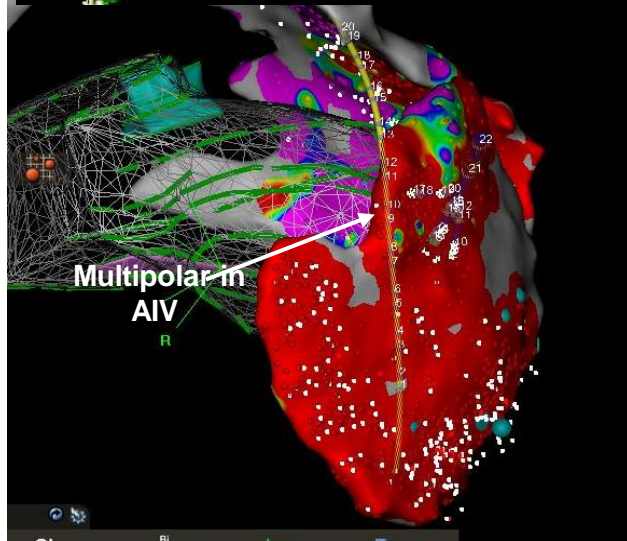
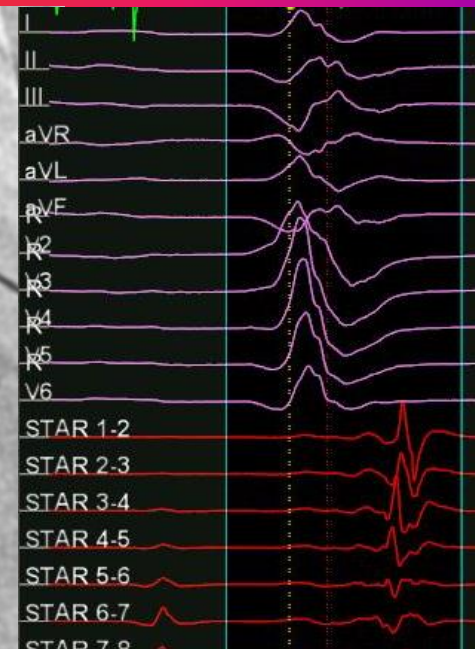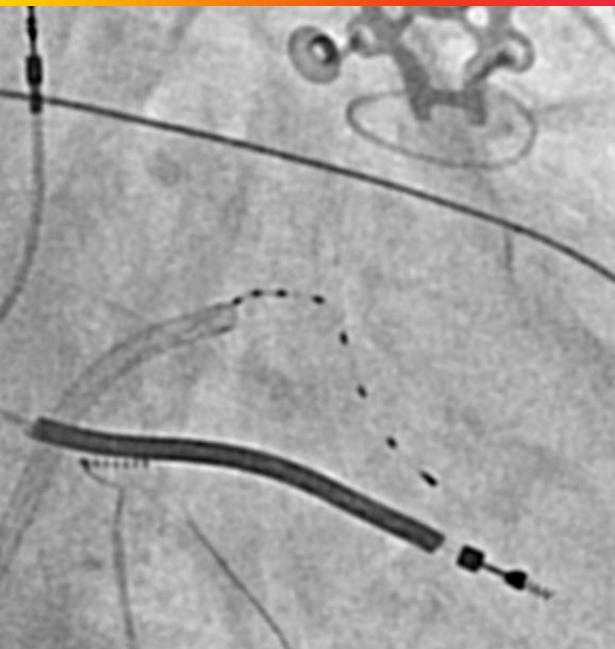
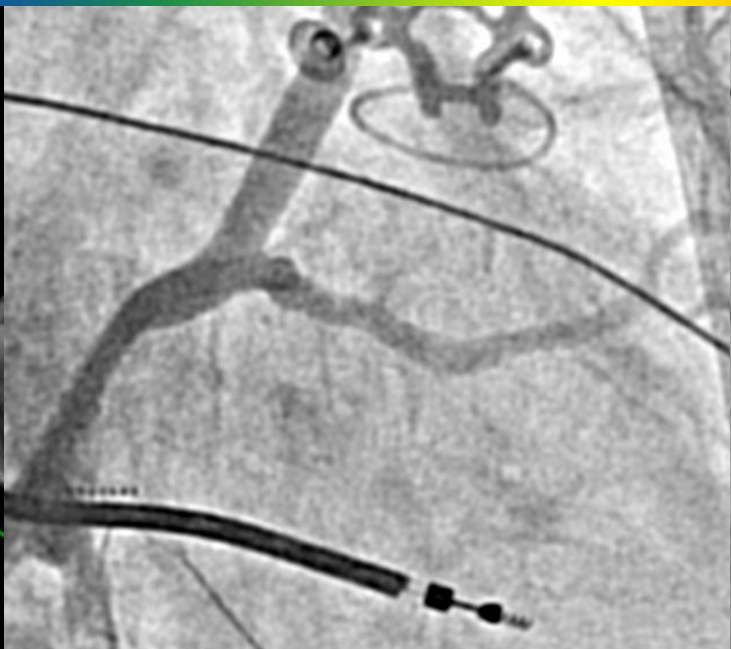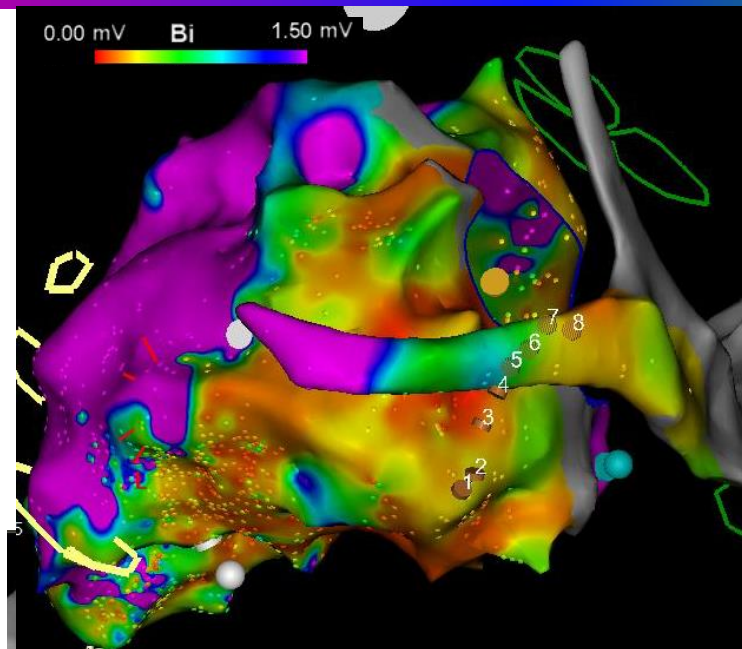
Da-Wariboko et al *Heart Rhythm*. 2020 Dec;17(12):2126-2134.



The infarct-related vein

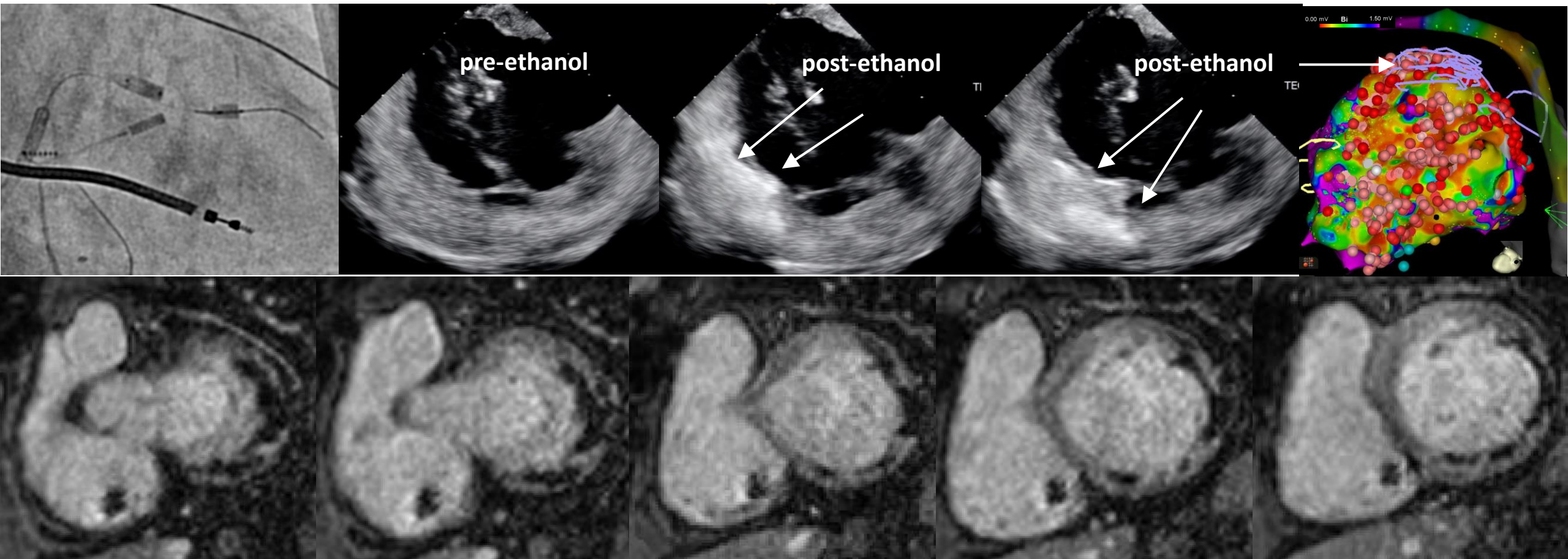


For every infarct, there is an epicardial vein



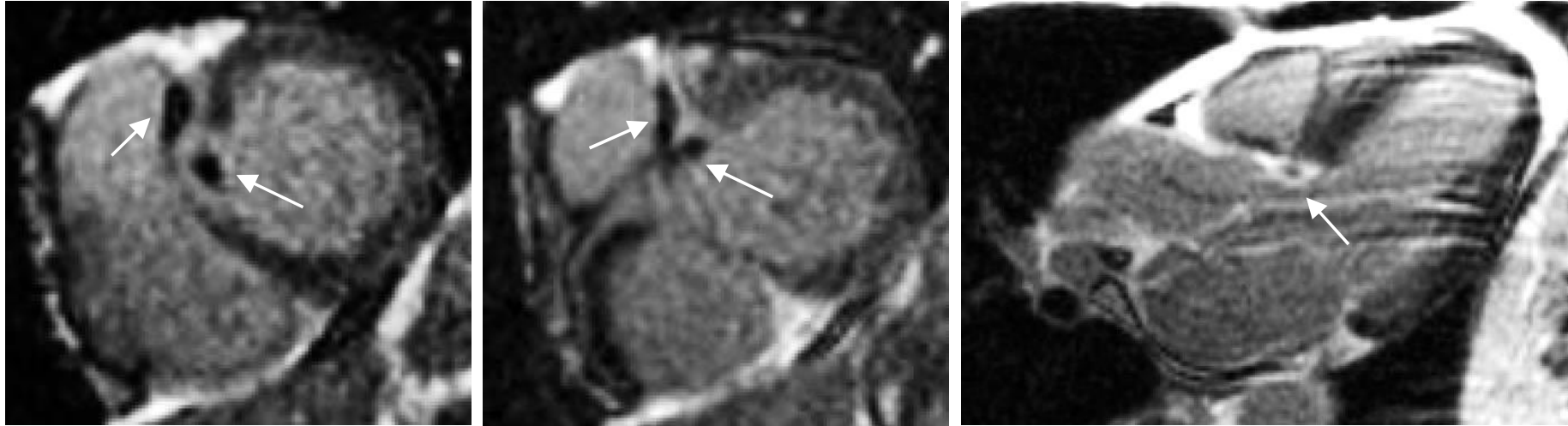
Ethanol-induced intramural ablation

Microvascular obstruction on CMR

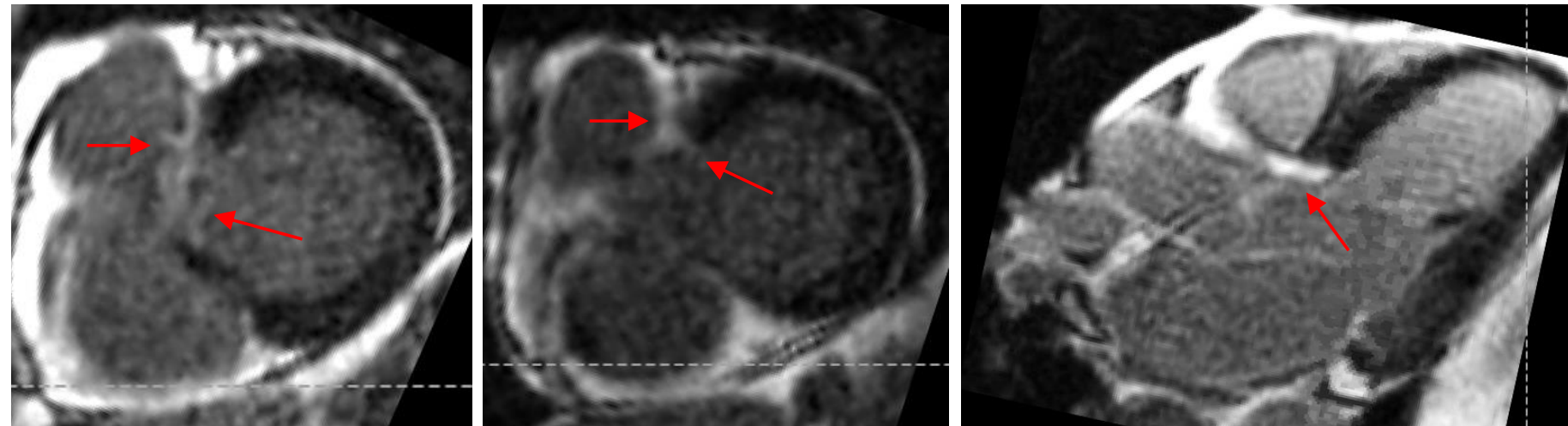


Microvascular occlusion replaced by scar

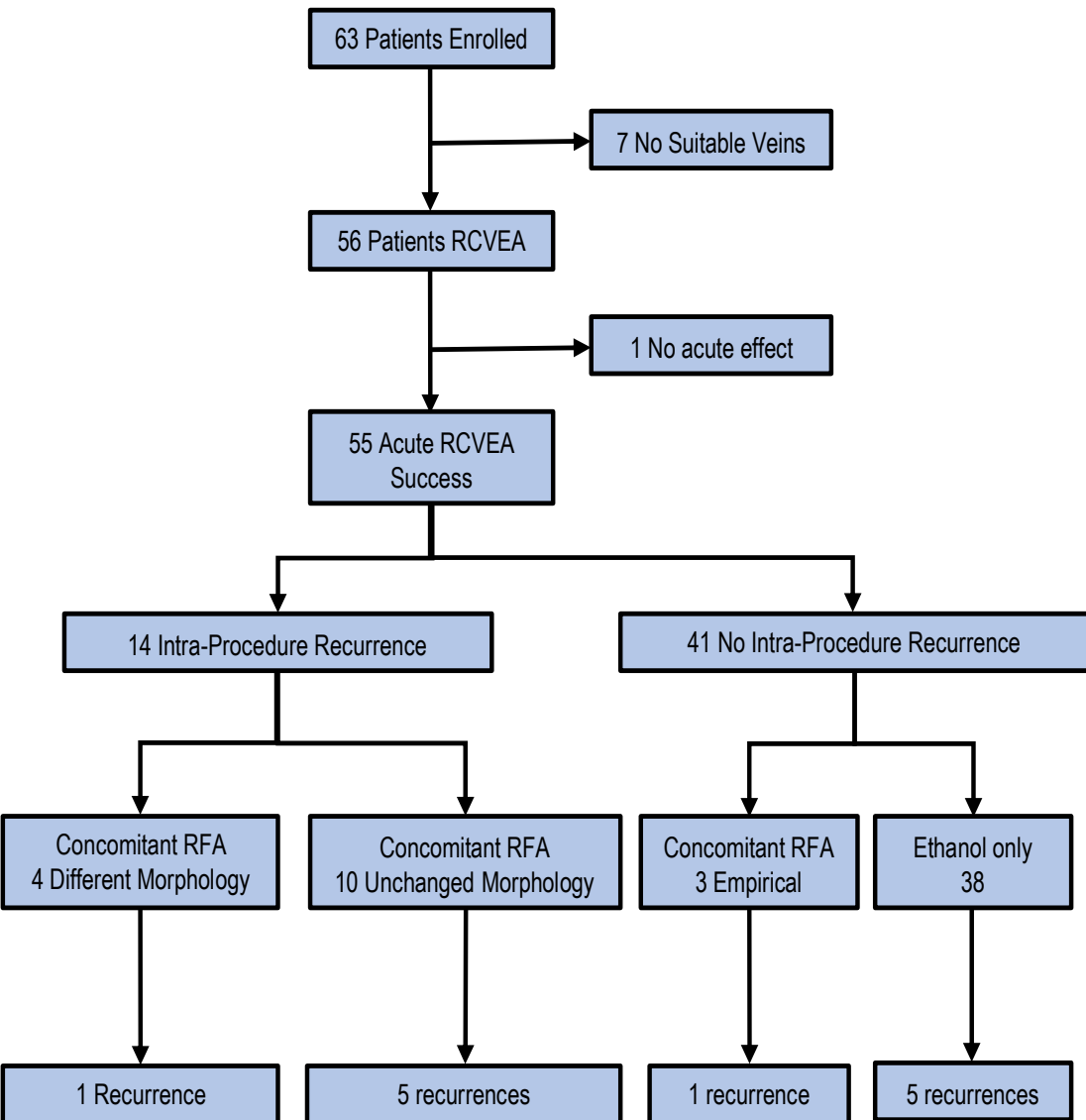
24 h post-ethanol



30 days post-ethanol

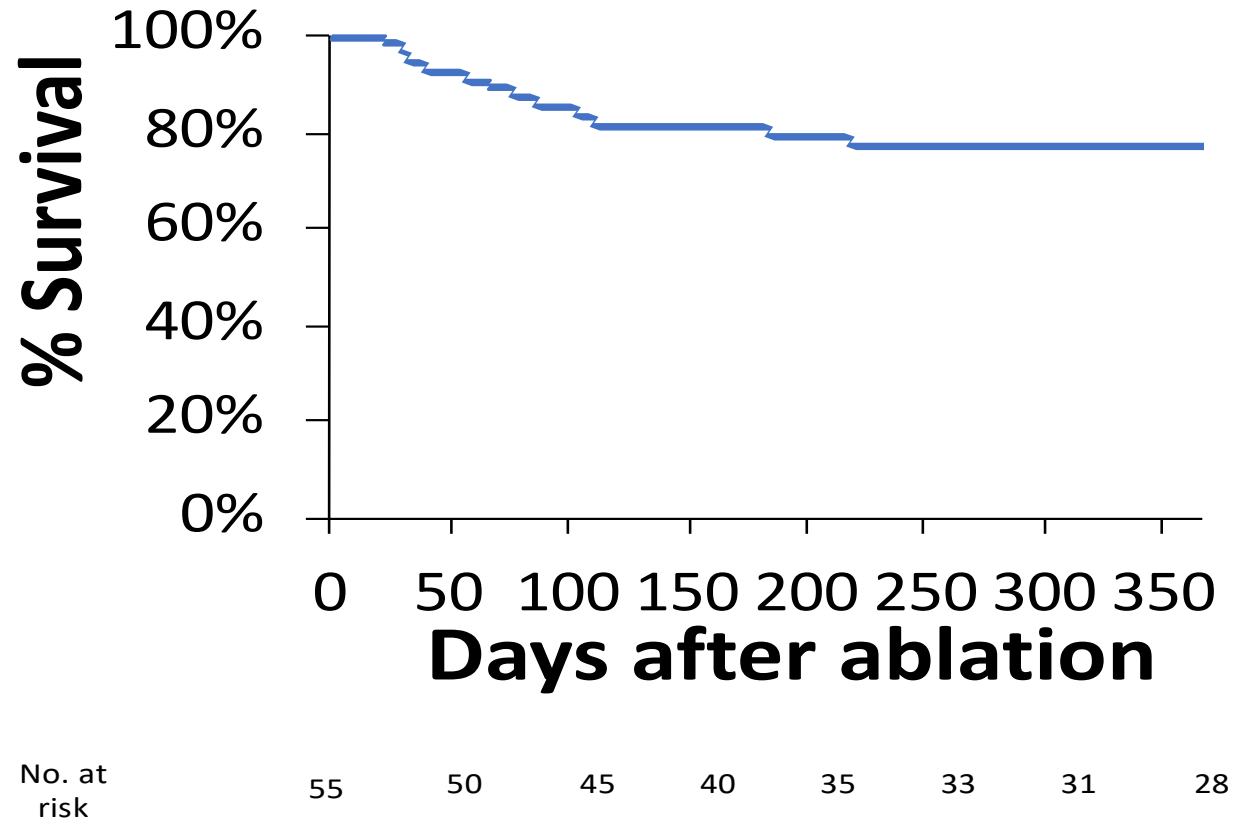


Venous ethanol for failed ablation: Outcomes



F

Freedom from ventricular arrhythmias

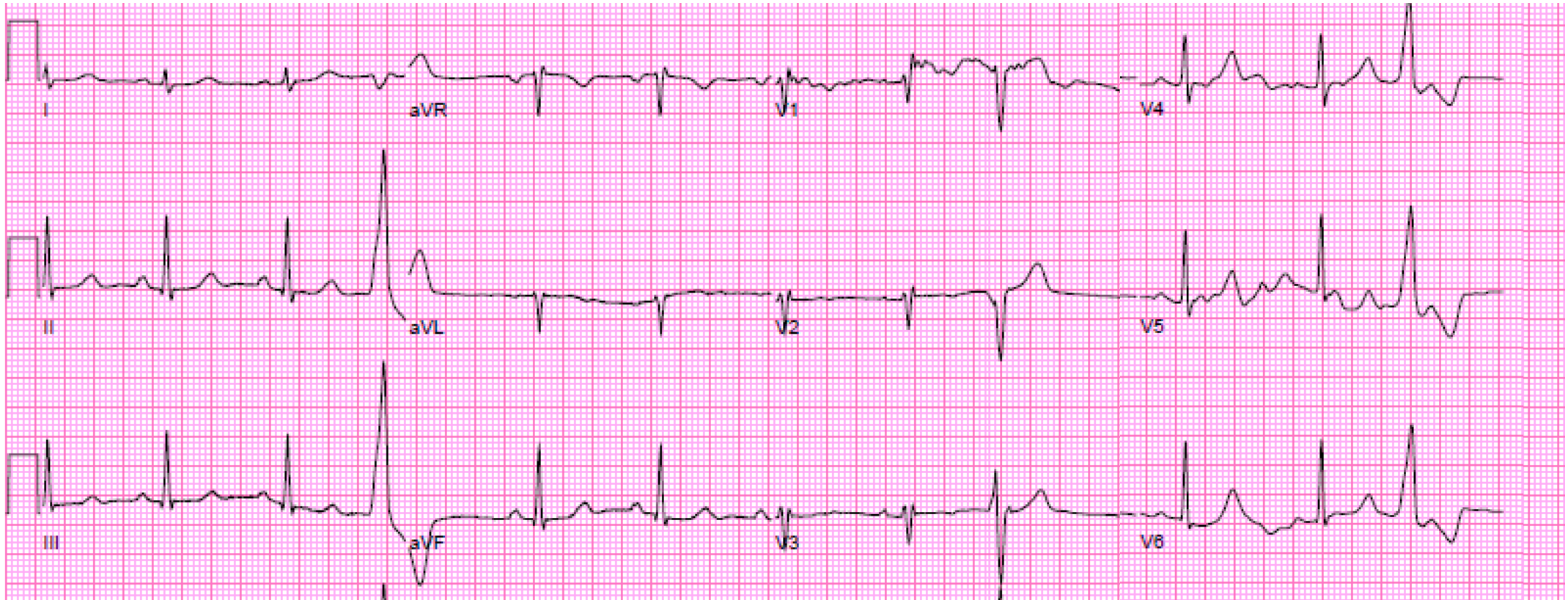


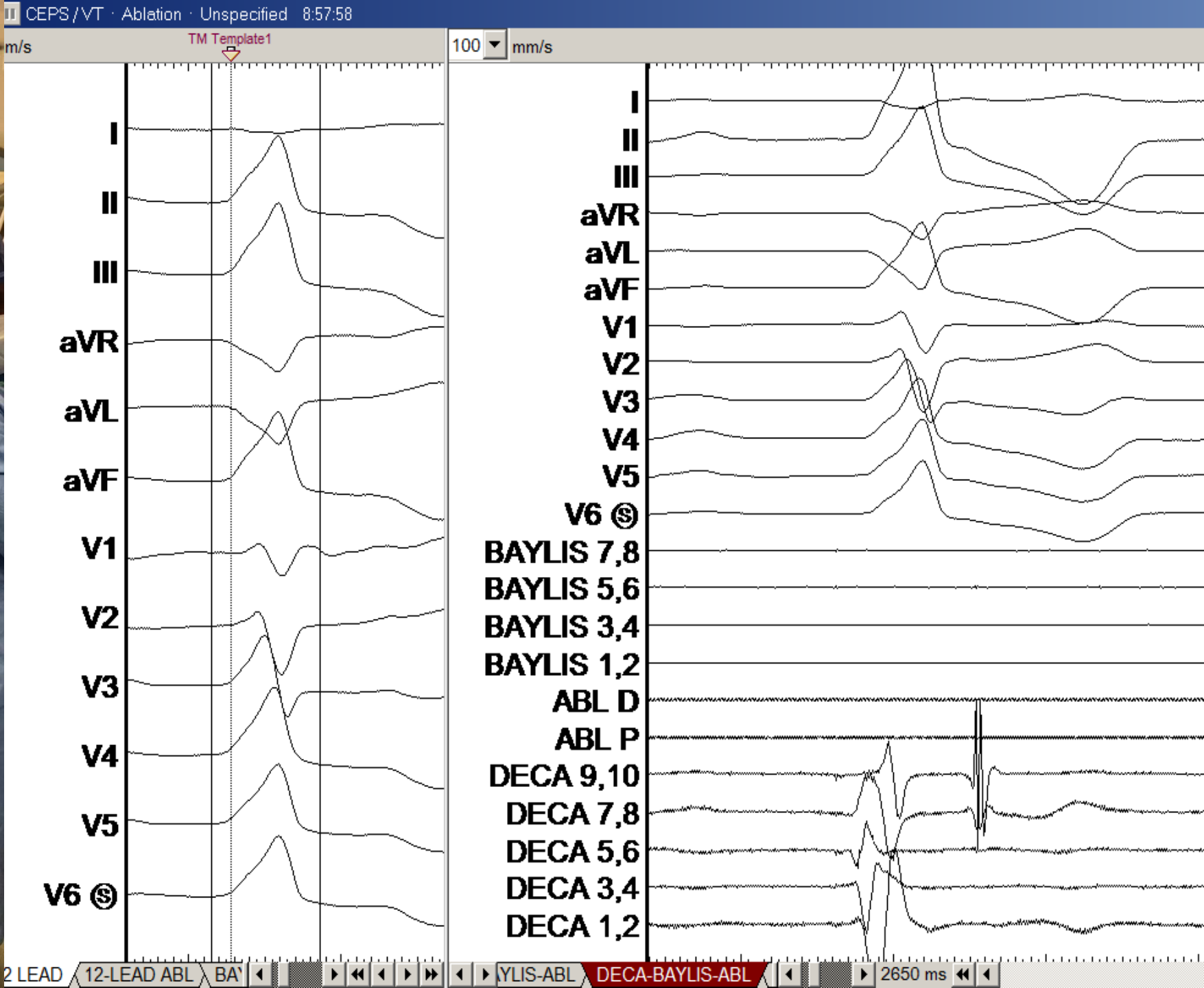
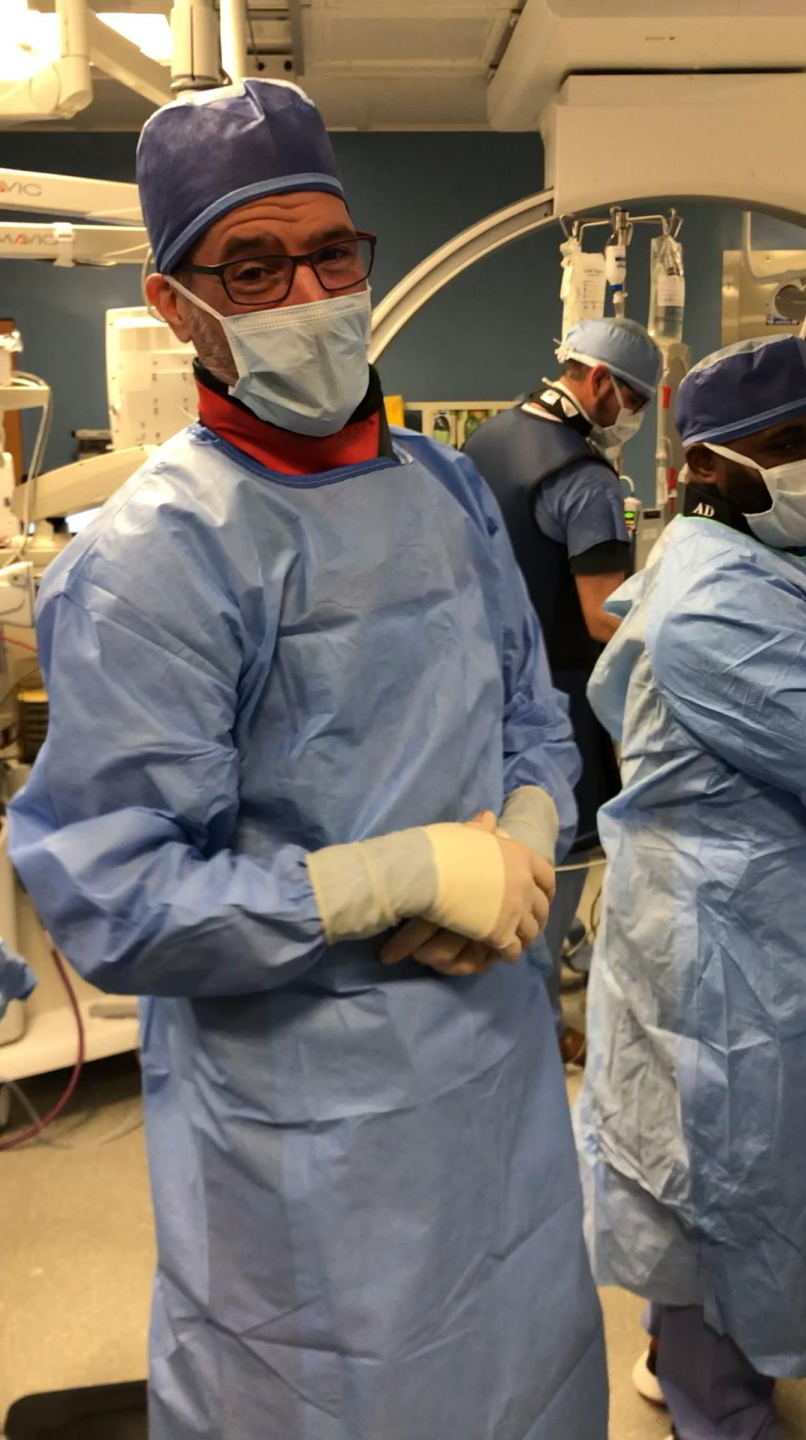Conclusions

- Venous ethanol can target intramural focal sources –LV summit and others
- Large tissue ablation with double-balloon technique is achieved in infarct-related veins for ischemic VT: Lateral veins and others
- Microvascular occlusion detected on CMR acutely is replaced by scar
- Venous anatomy is challenging and variable and determines ethanol success
- Venous ethanol is a valuable tool for failed ablations of ventricular arrhythmias with 76% success at 1 year followup

54 y/o woman with recurrent palpitations

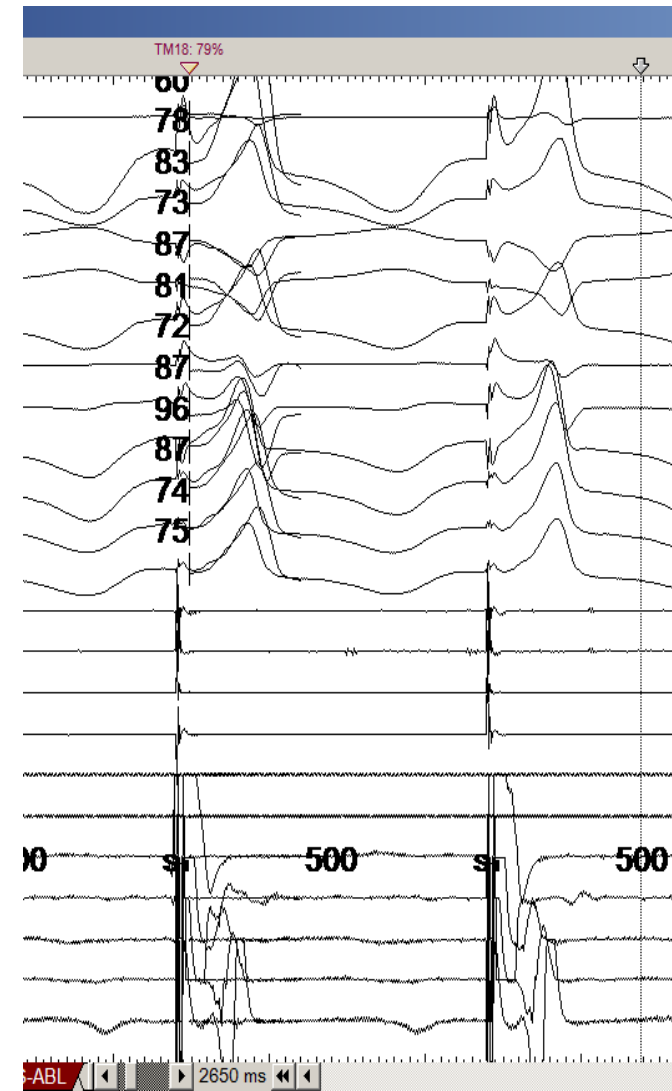
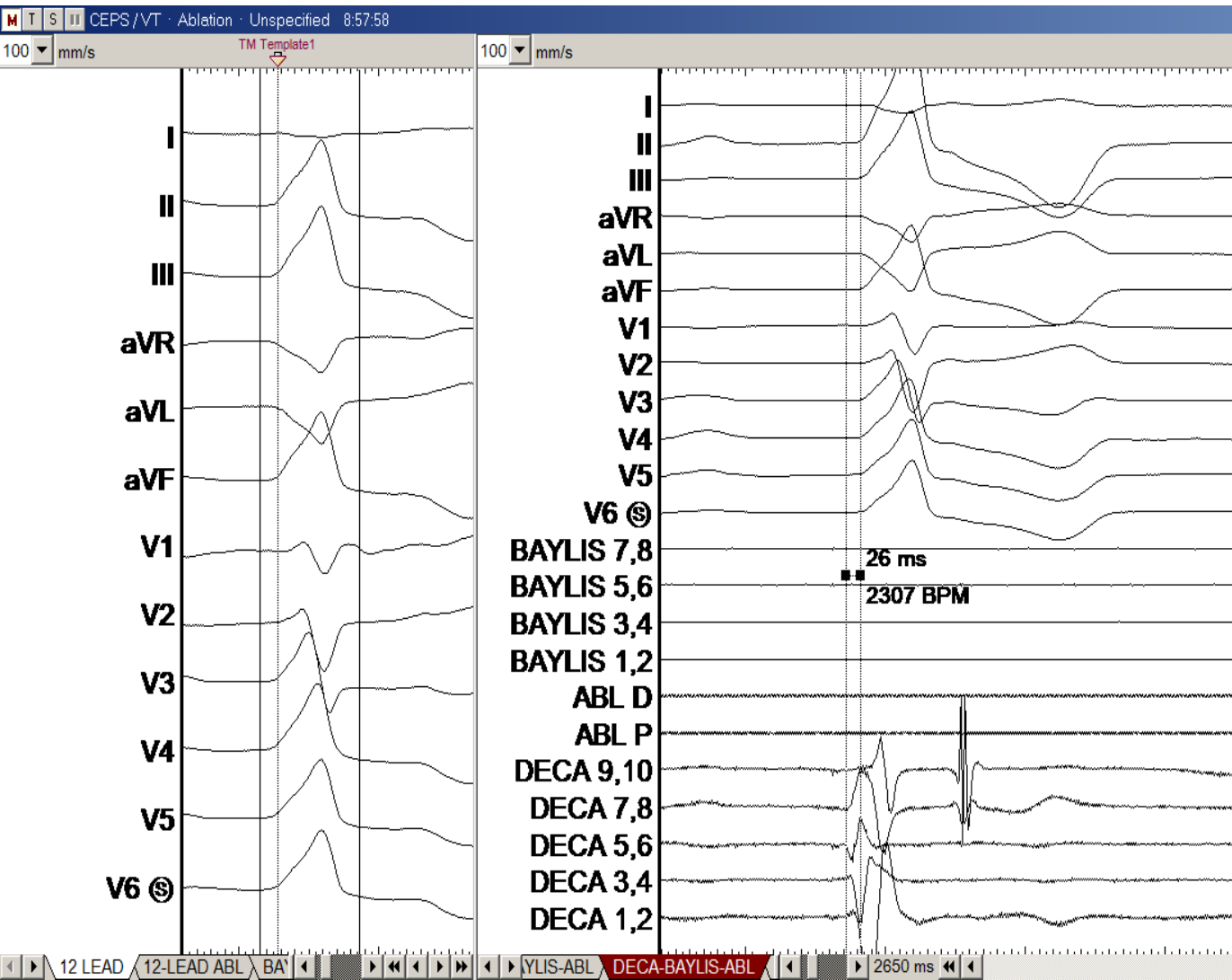
- Previous marathon runner. Palpitations for 3 years
- Failed ablation x2 elsewhere

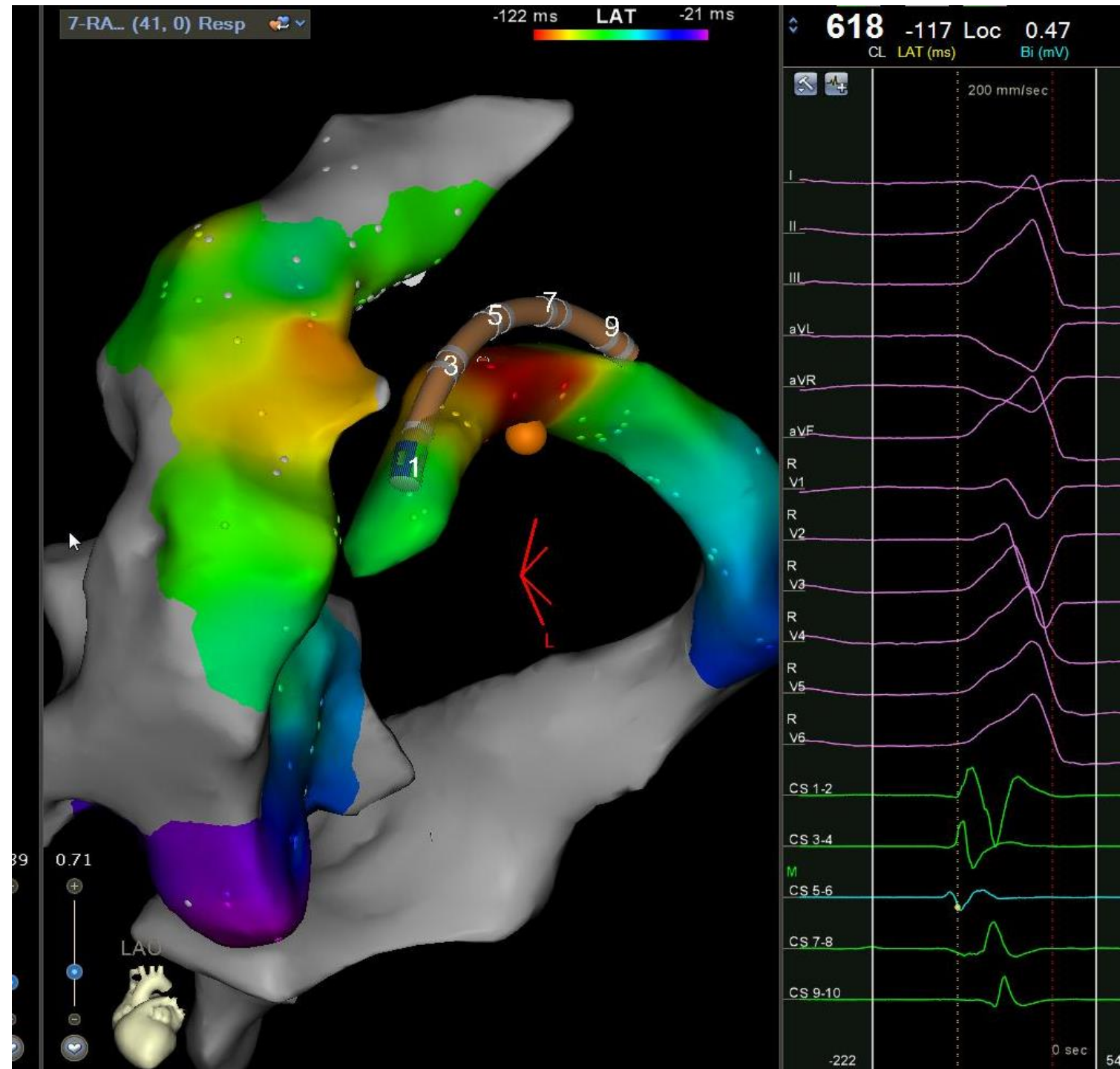
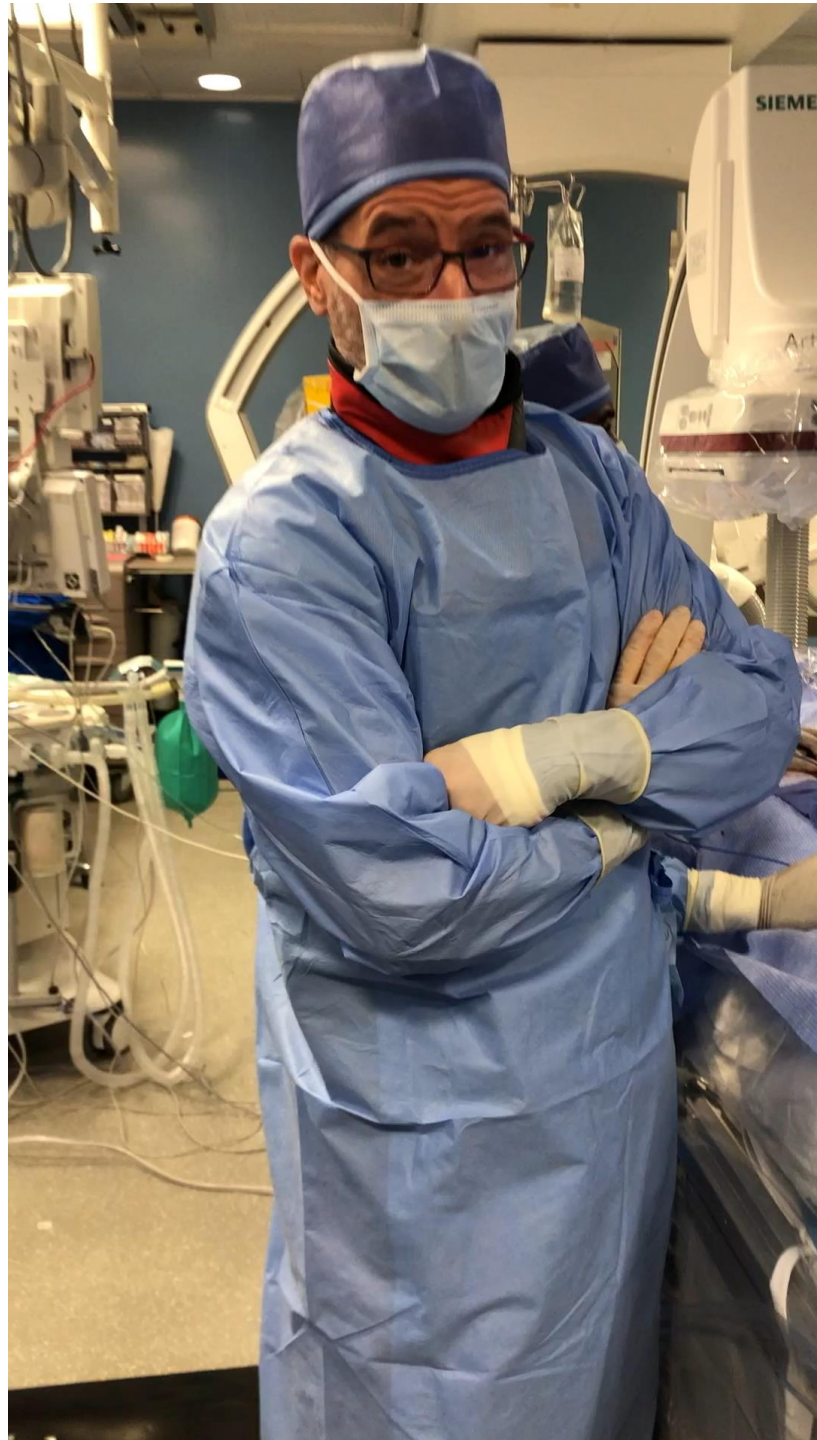
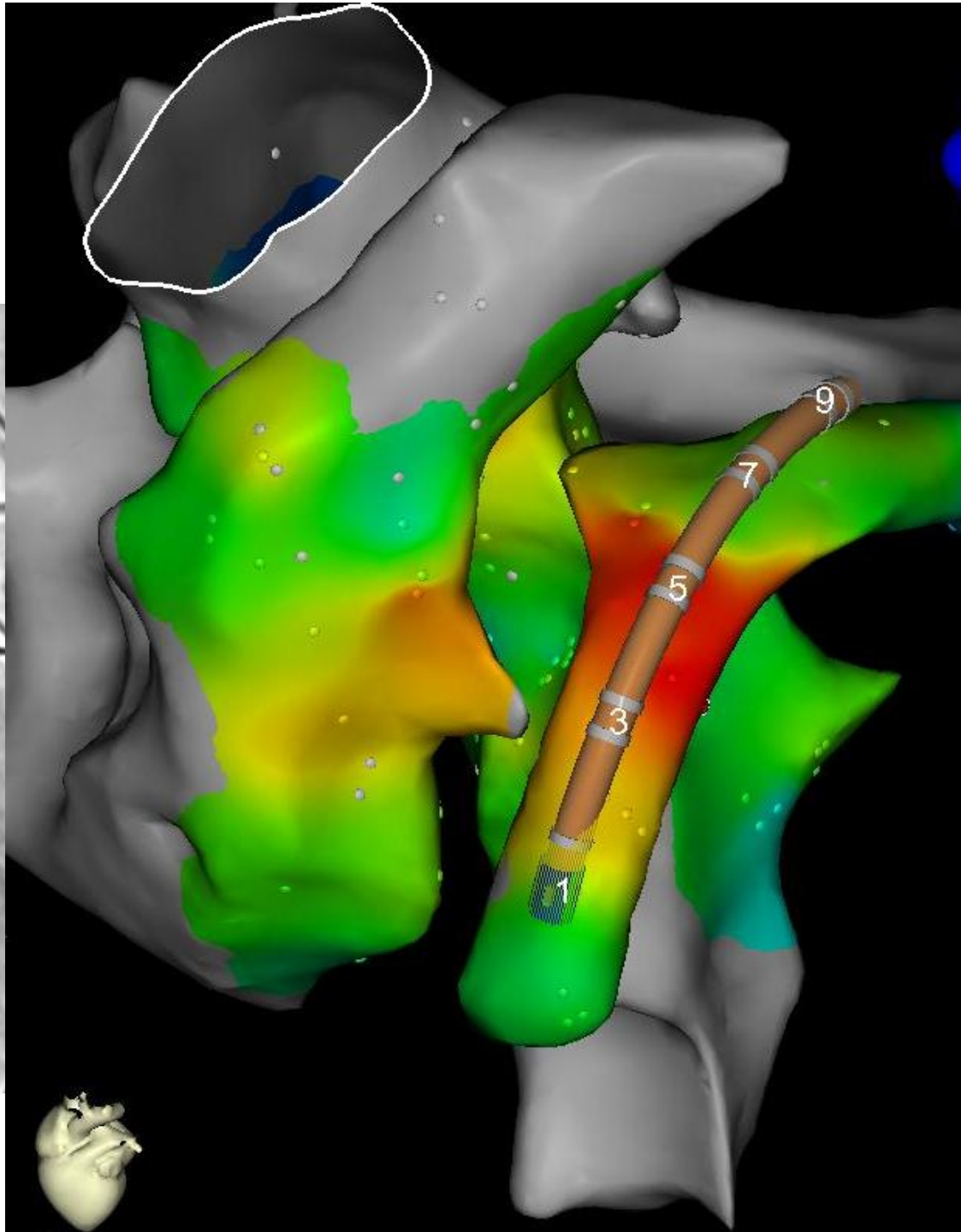
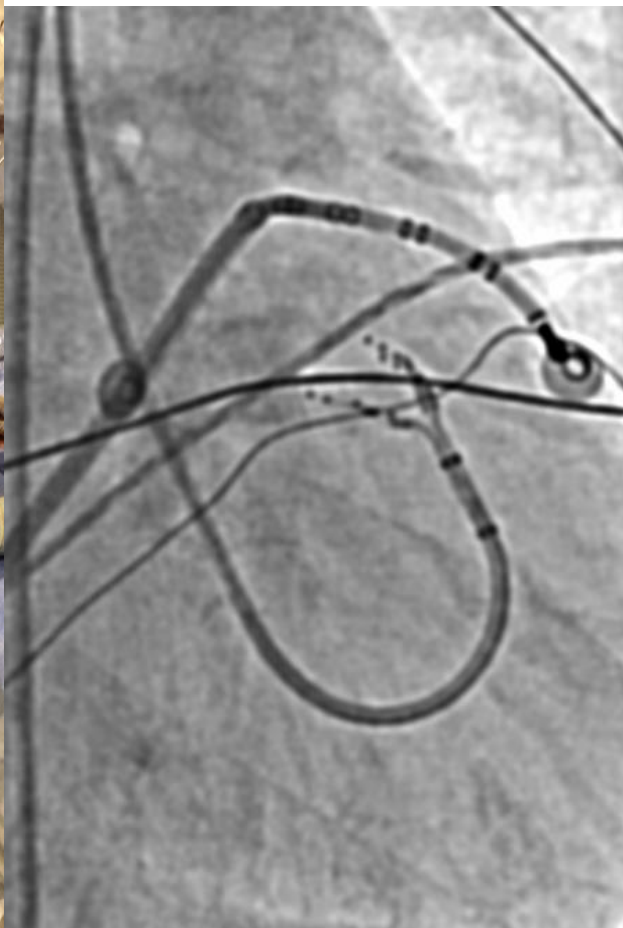


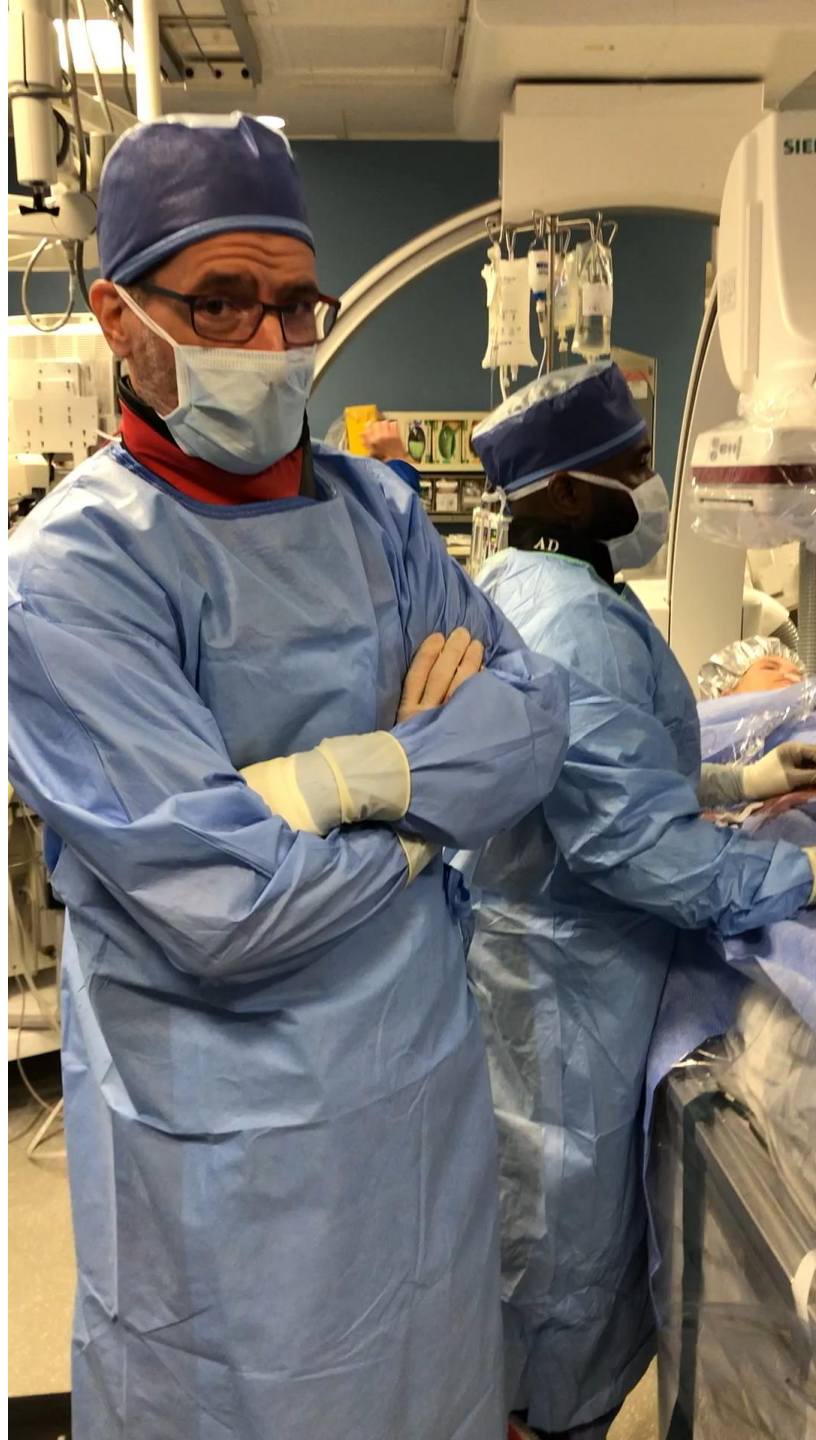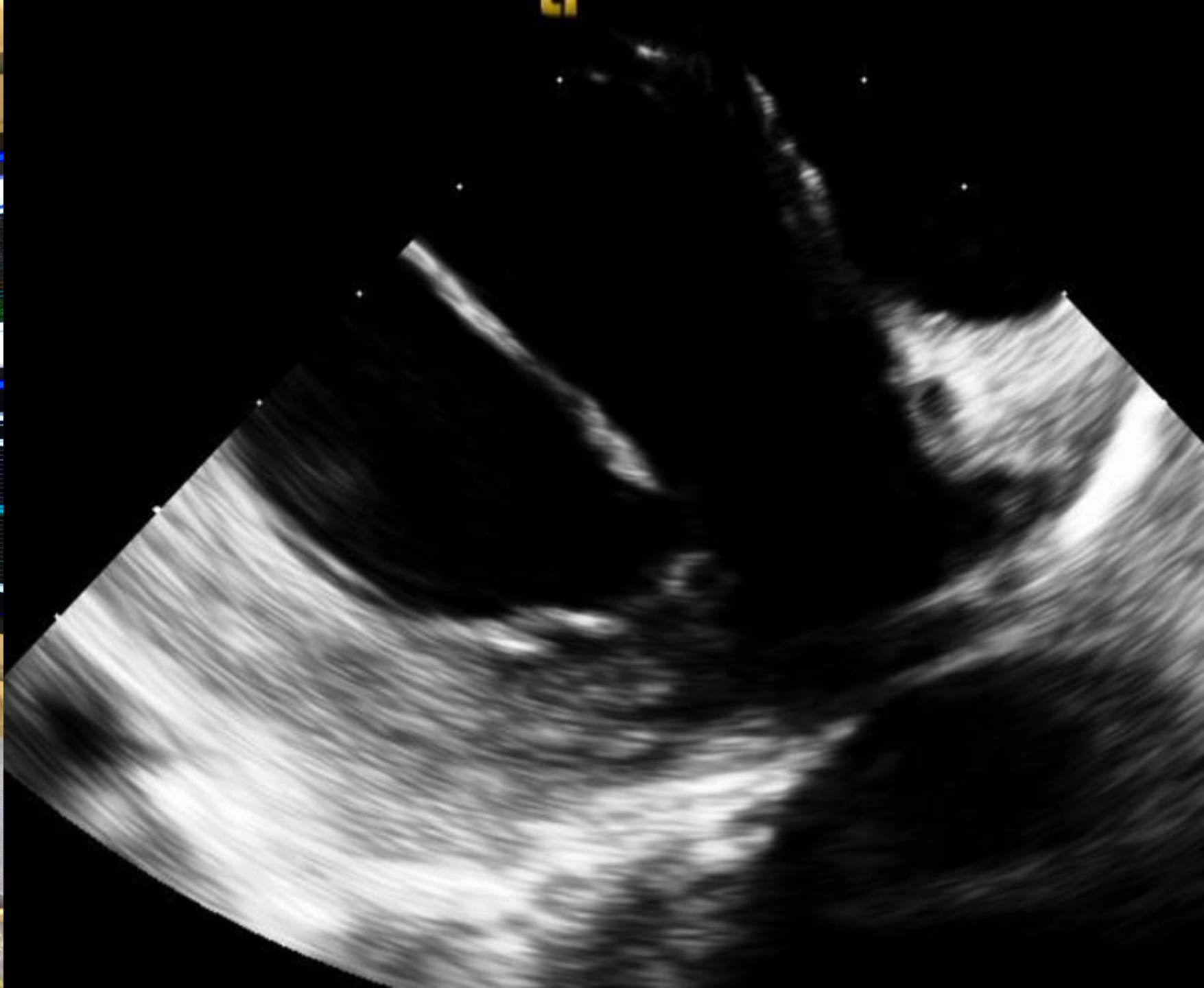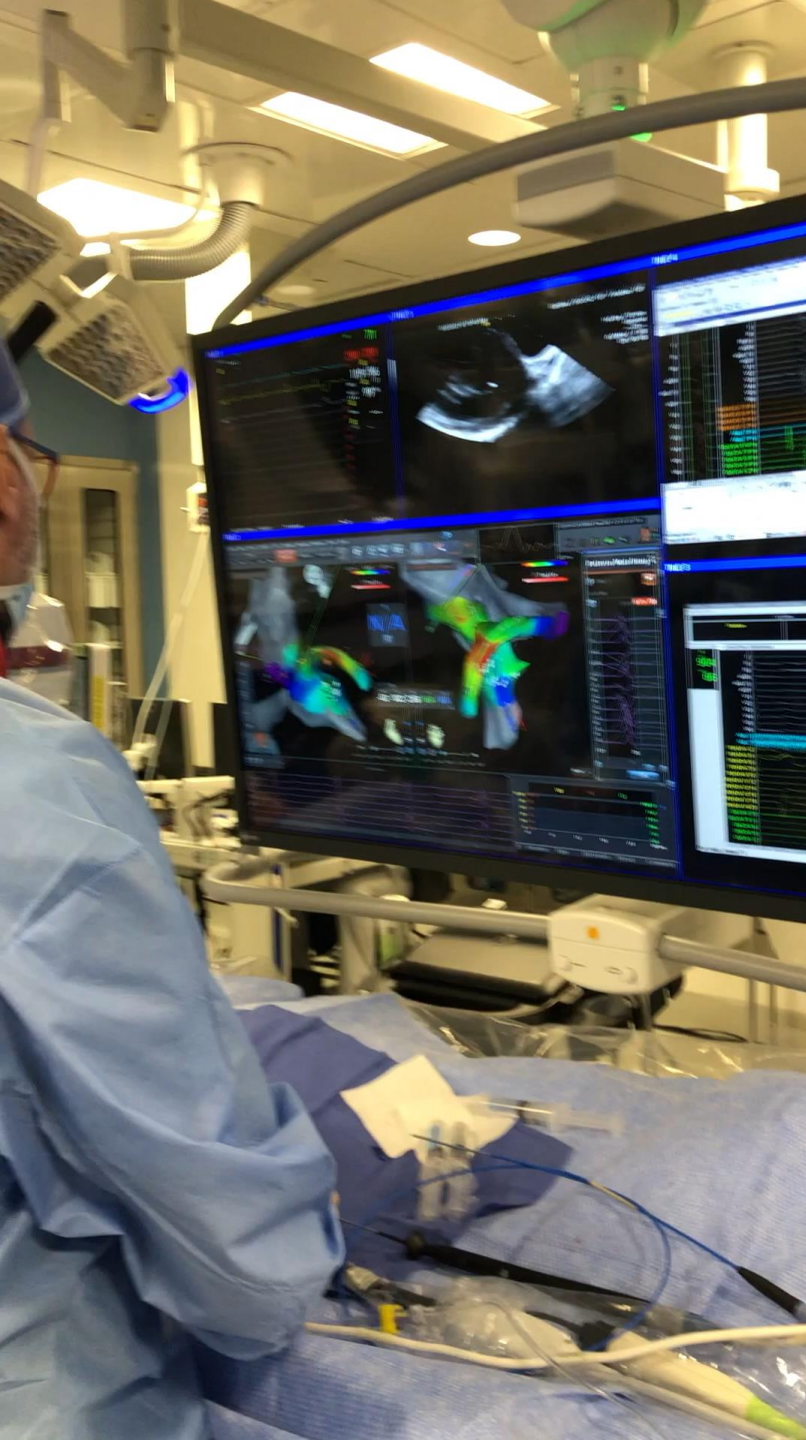Signal from AIV

26 msec pre-QRS, 79% pace-map match

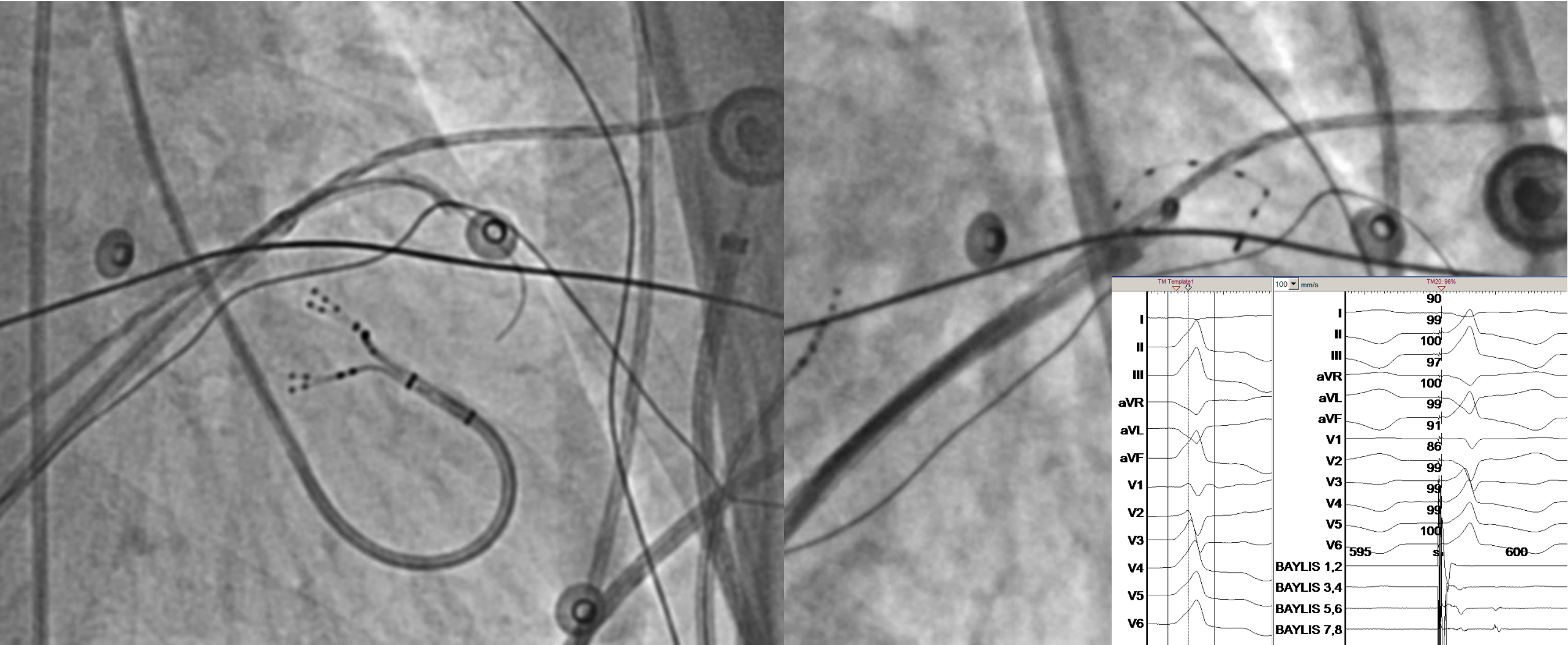


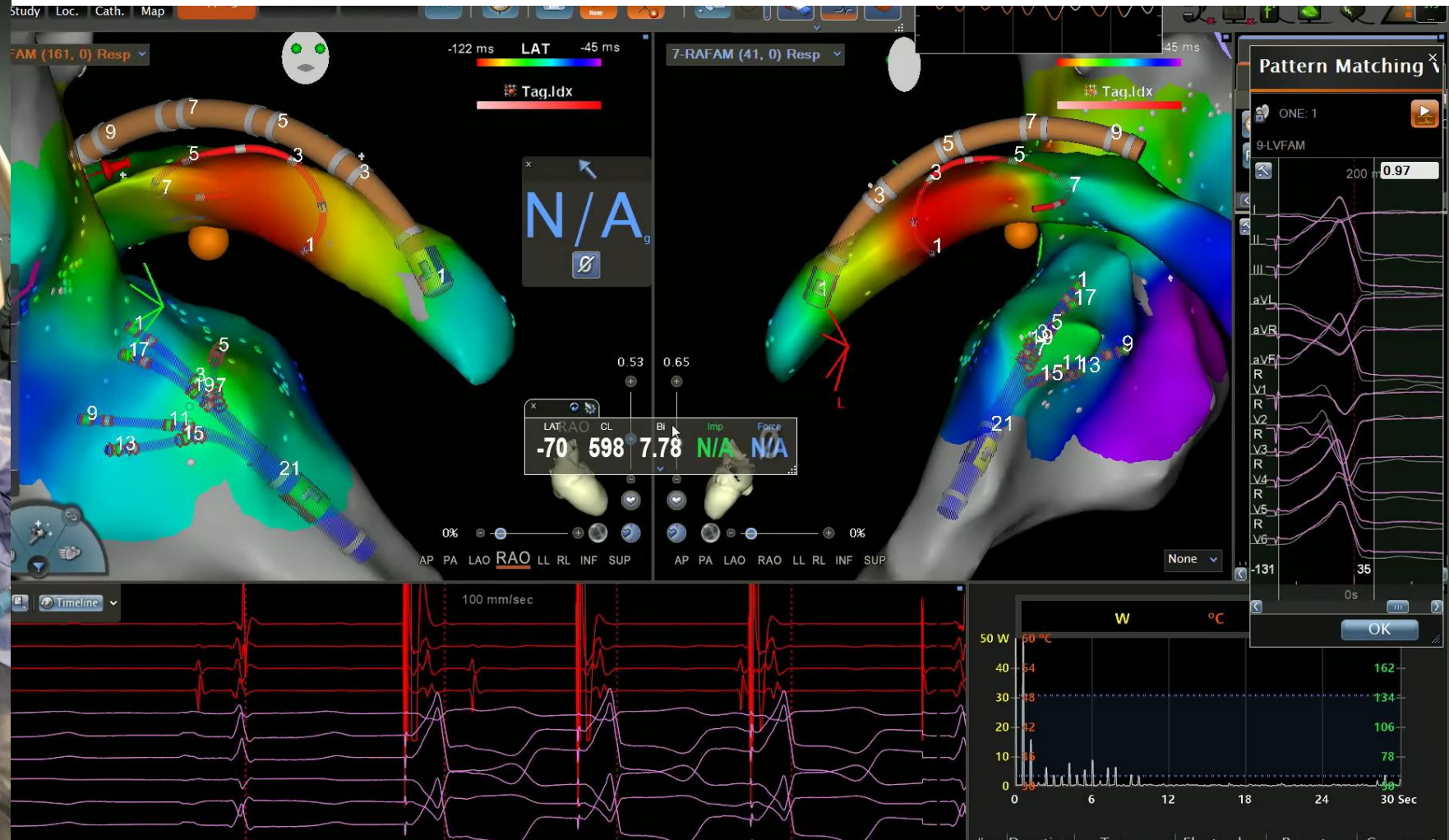
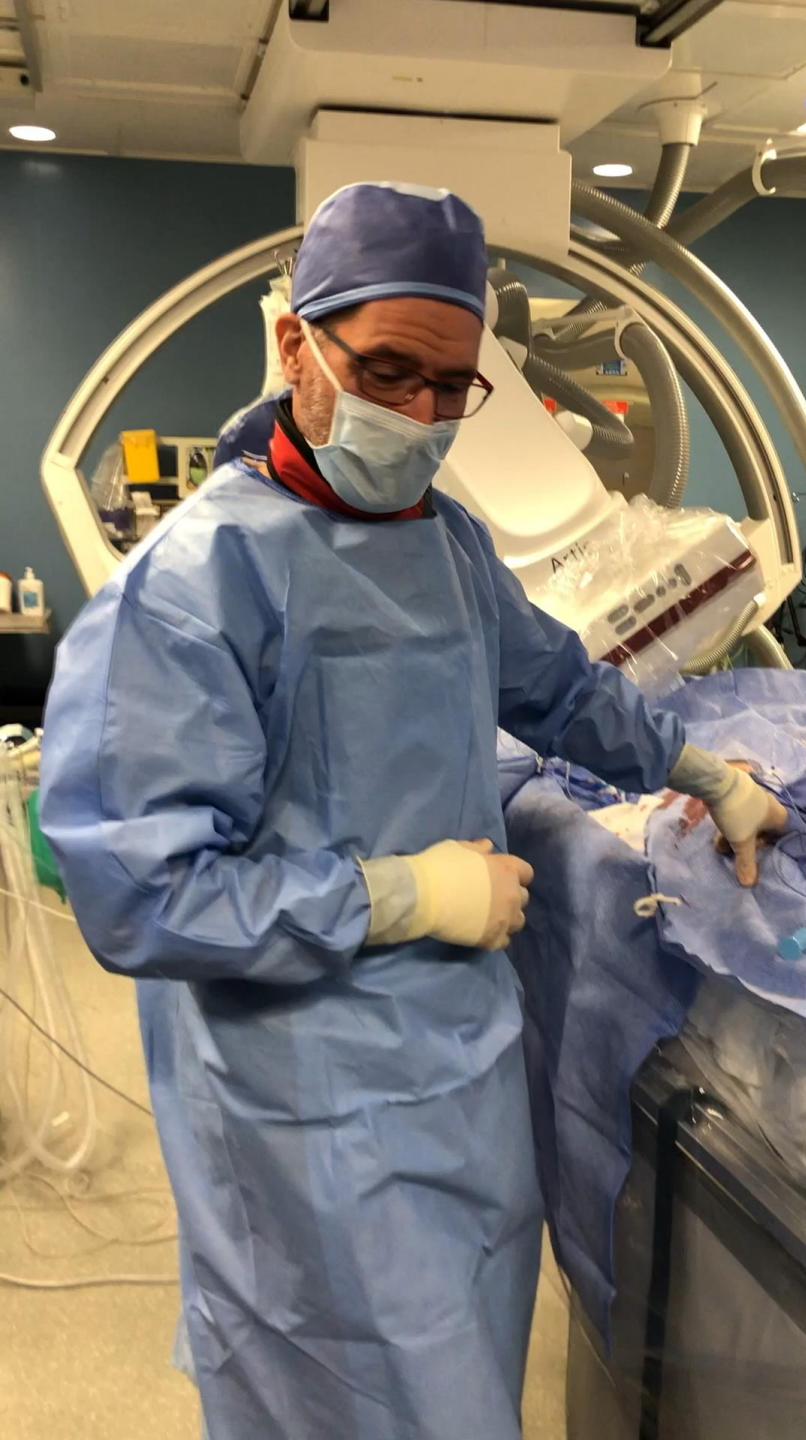

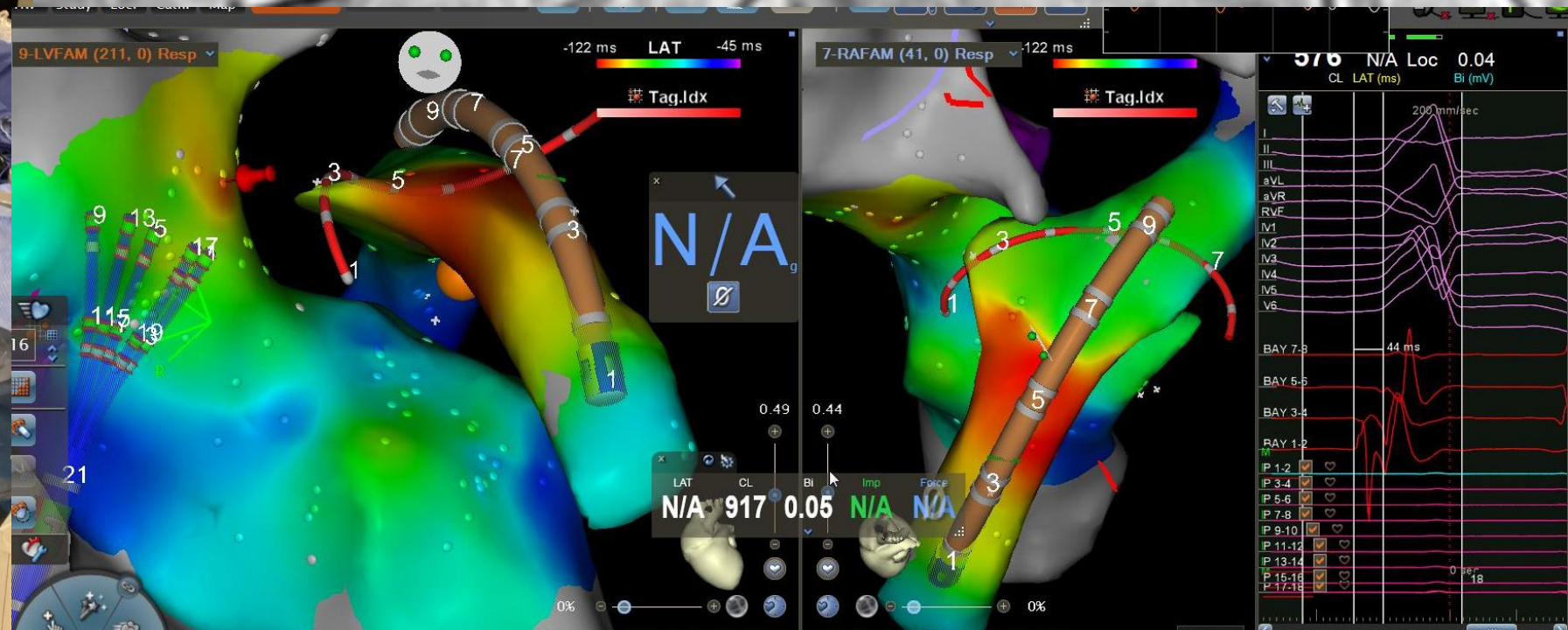

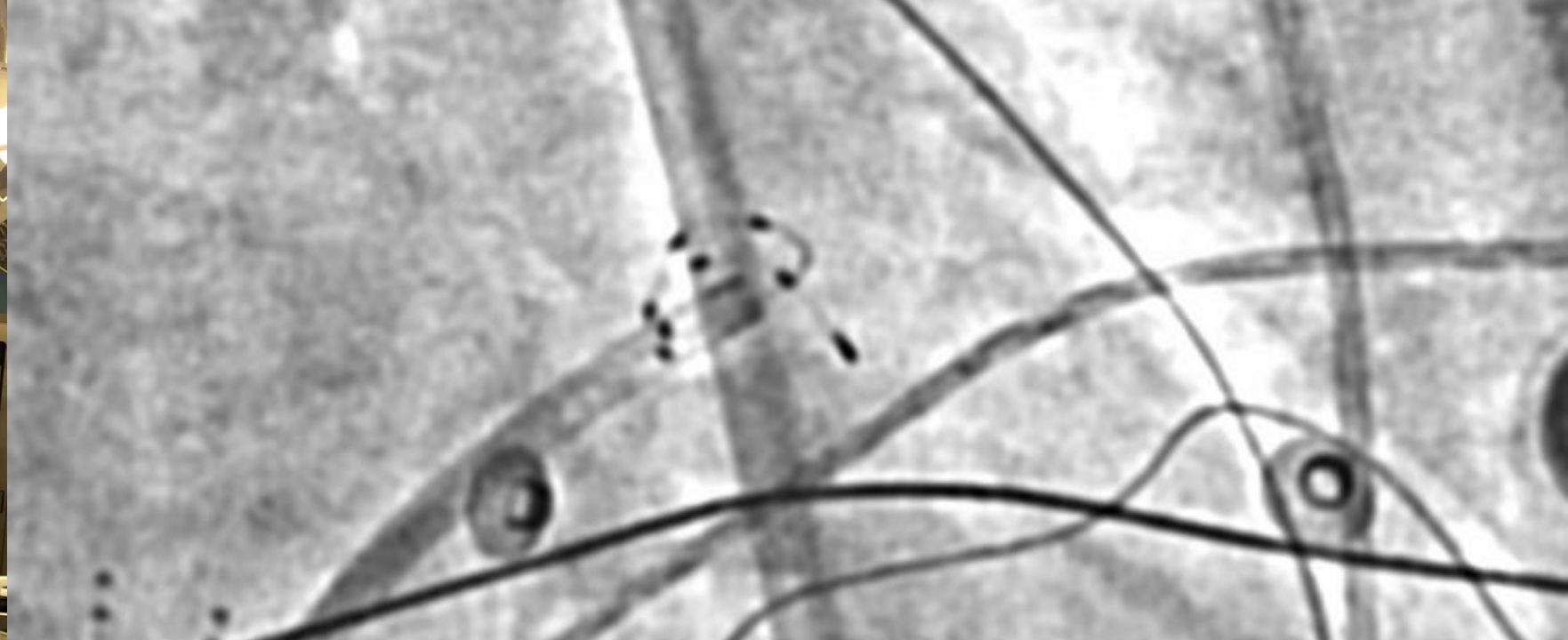
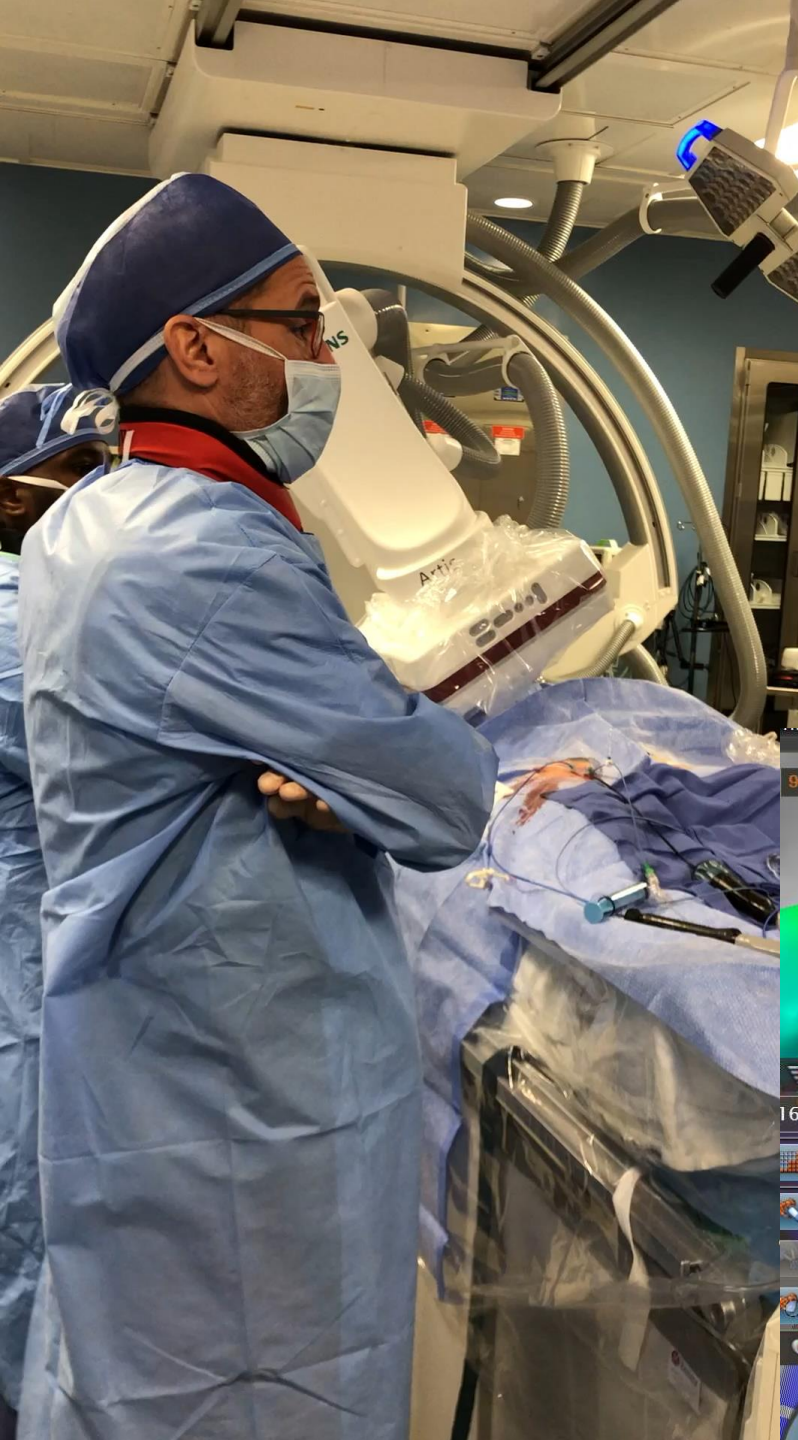

AIV venograms and AIV septal cannulation

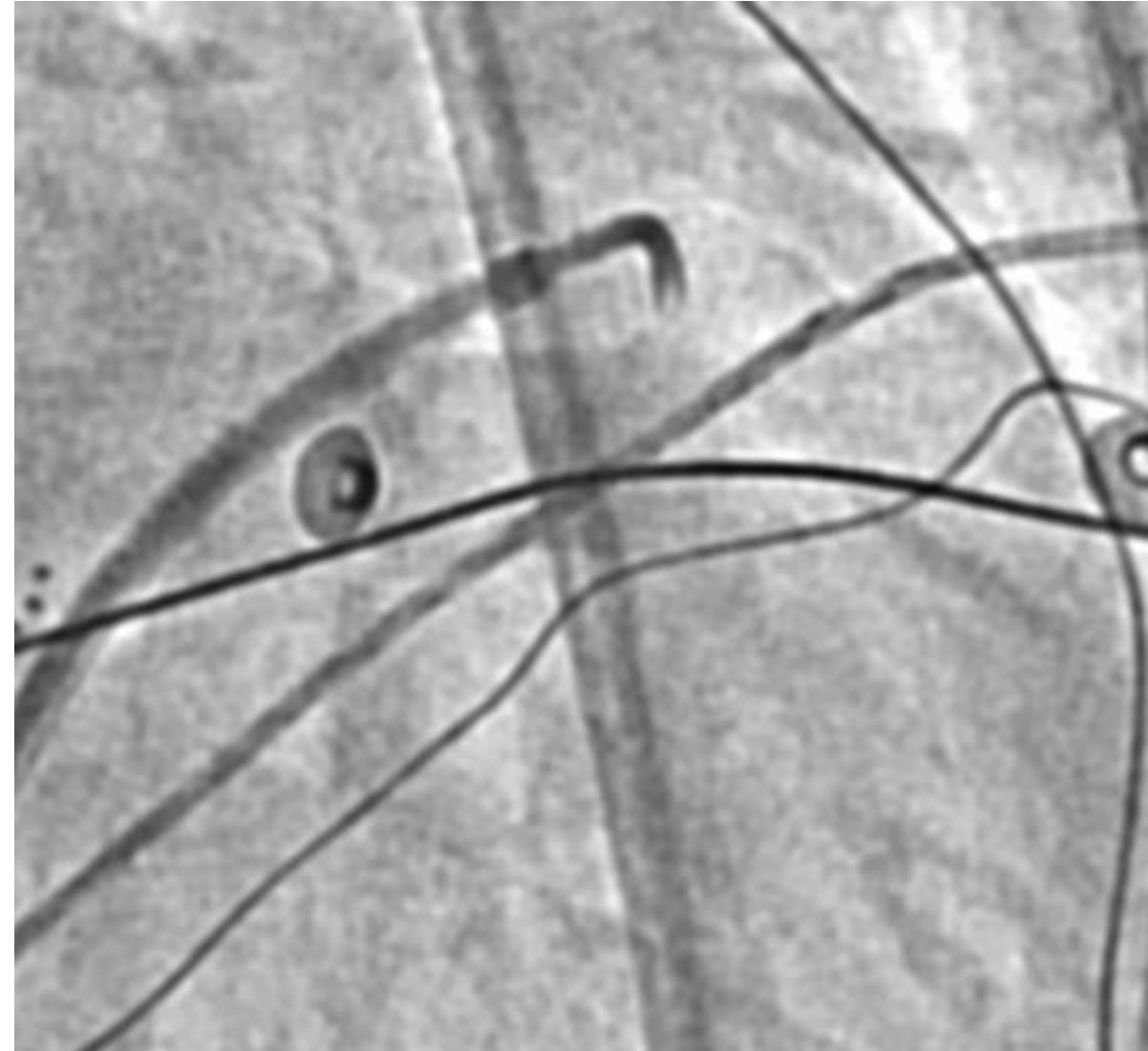
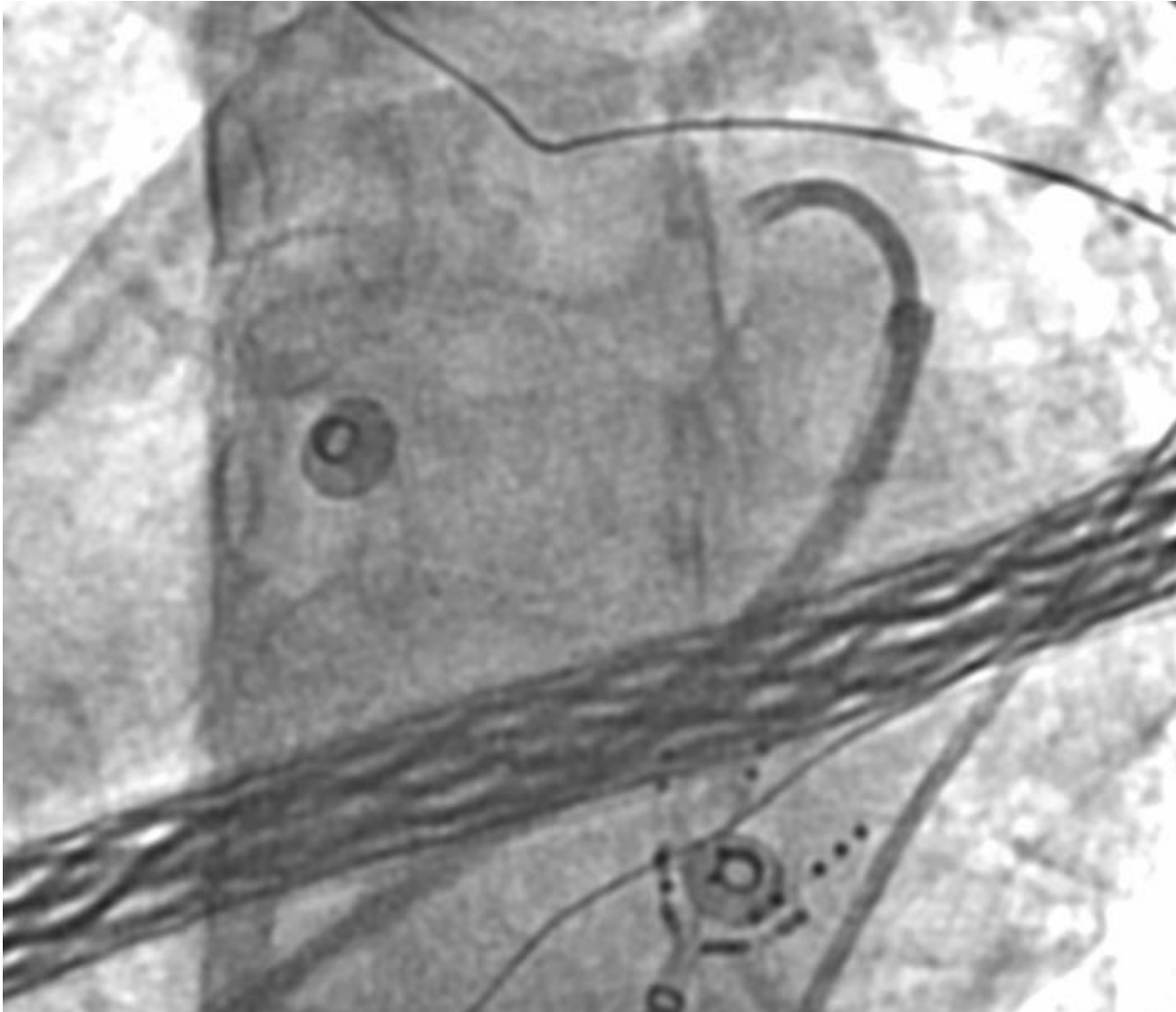




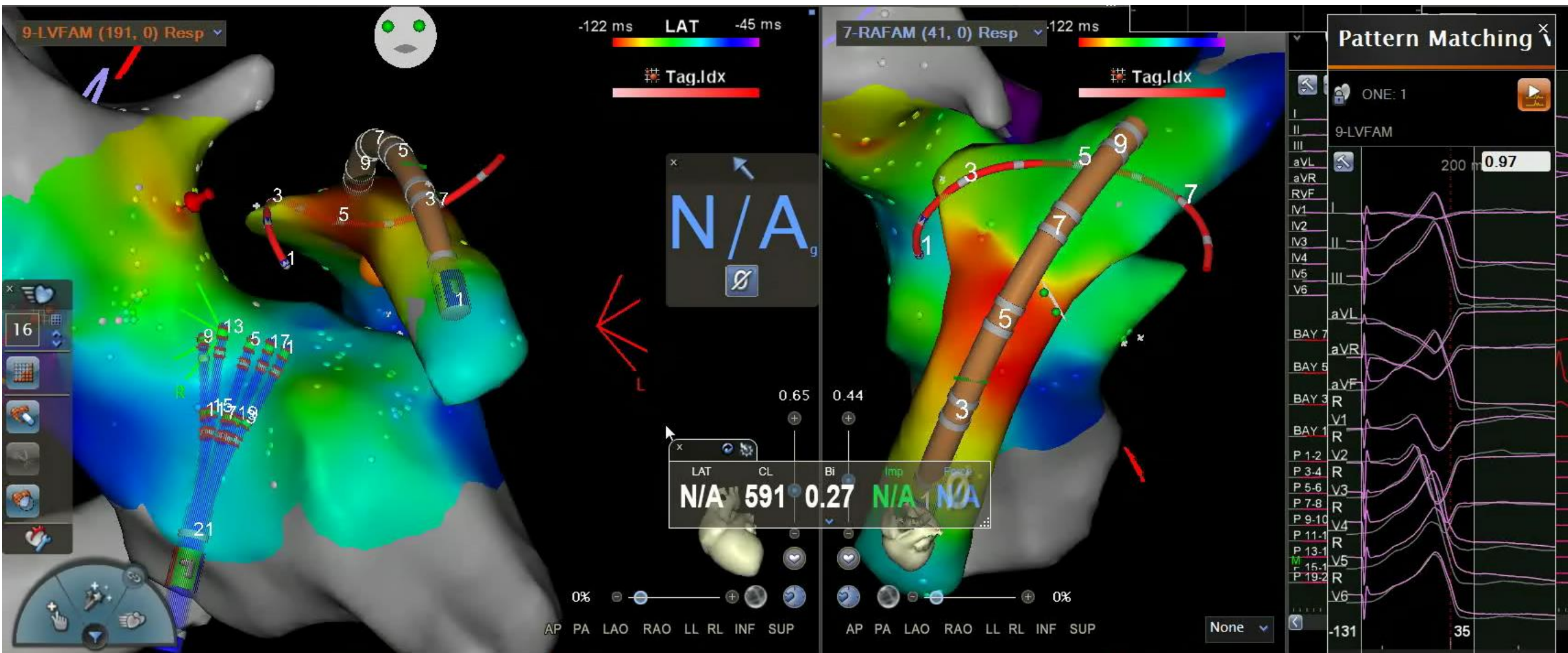


LV annular vein parallel to AIV

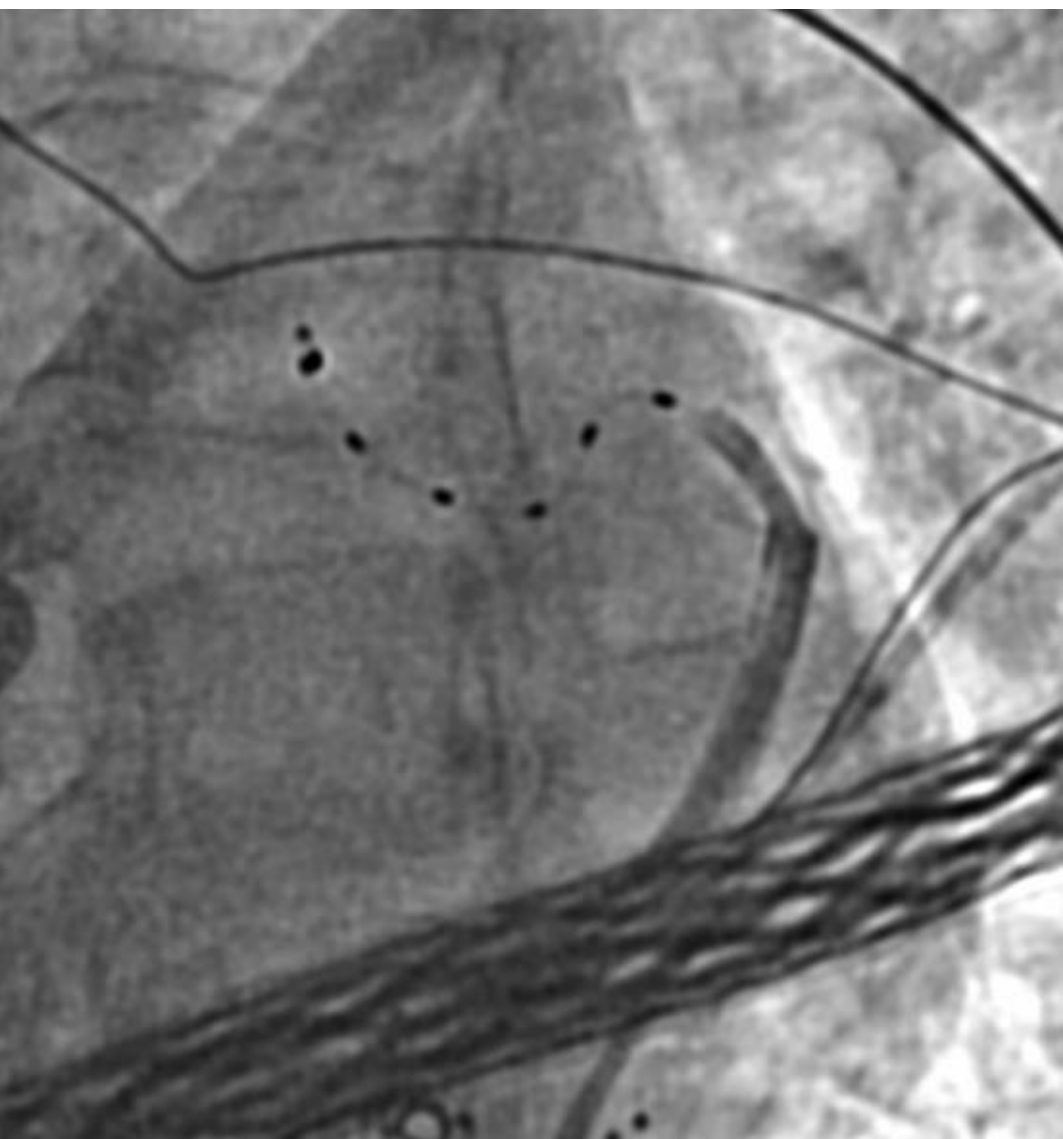
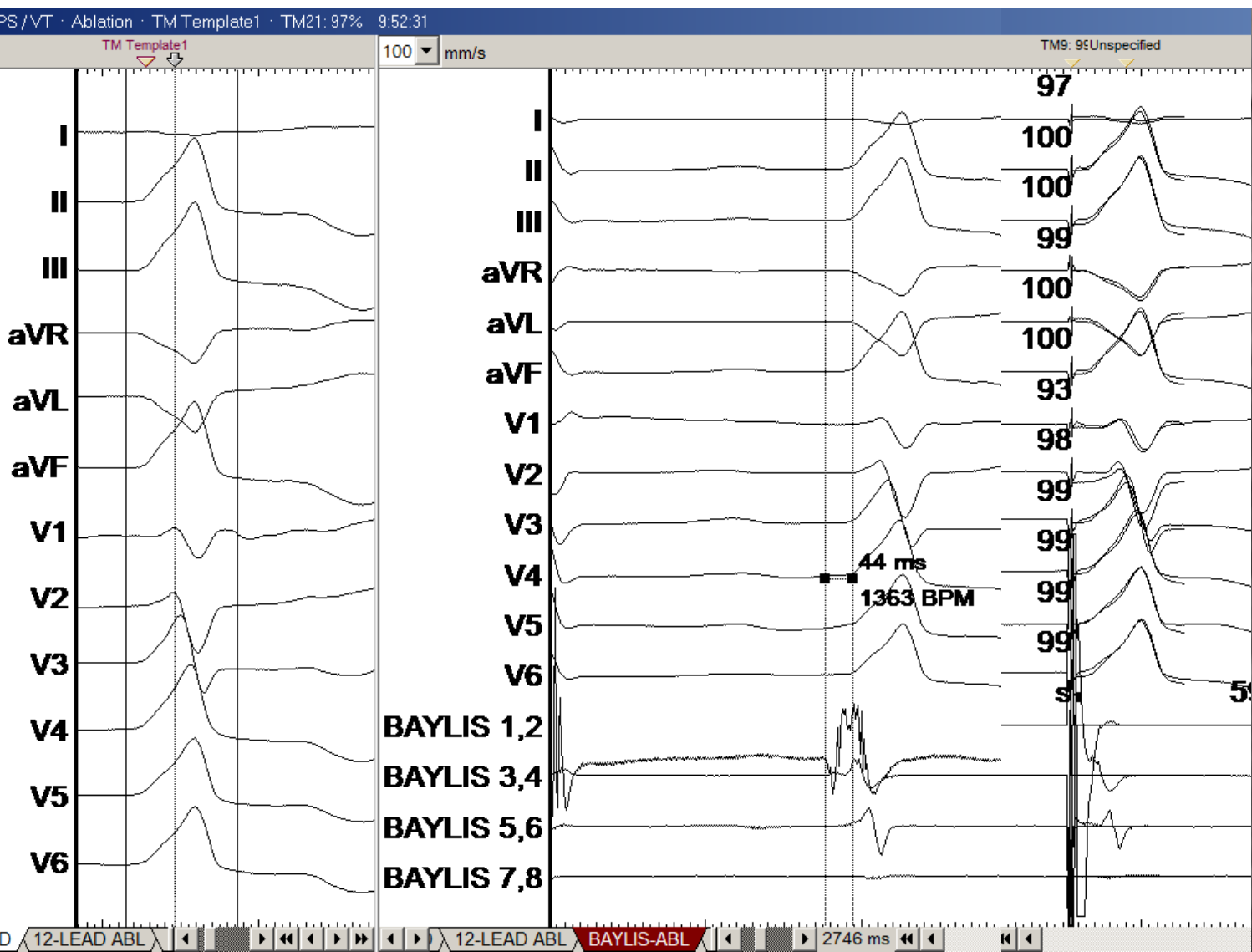
The importance of LAO caudal projection

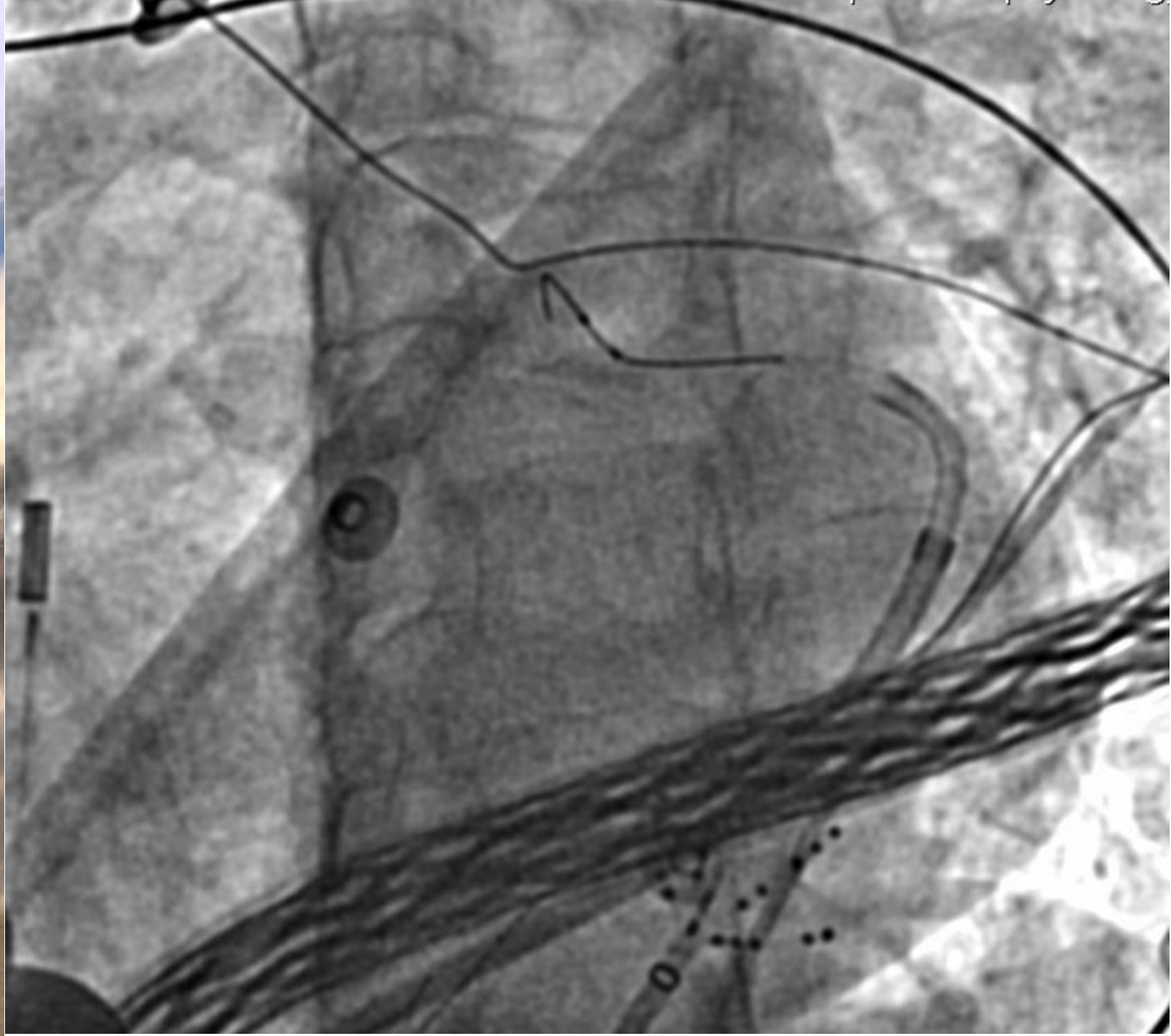
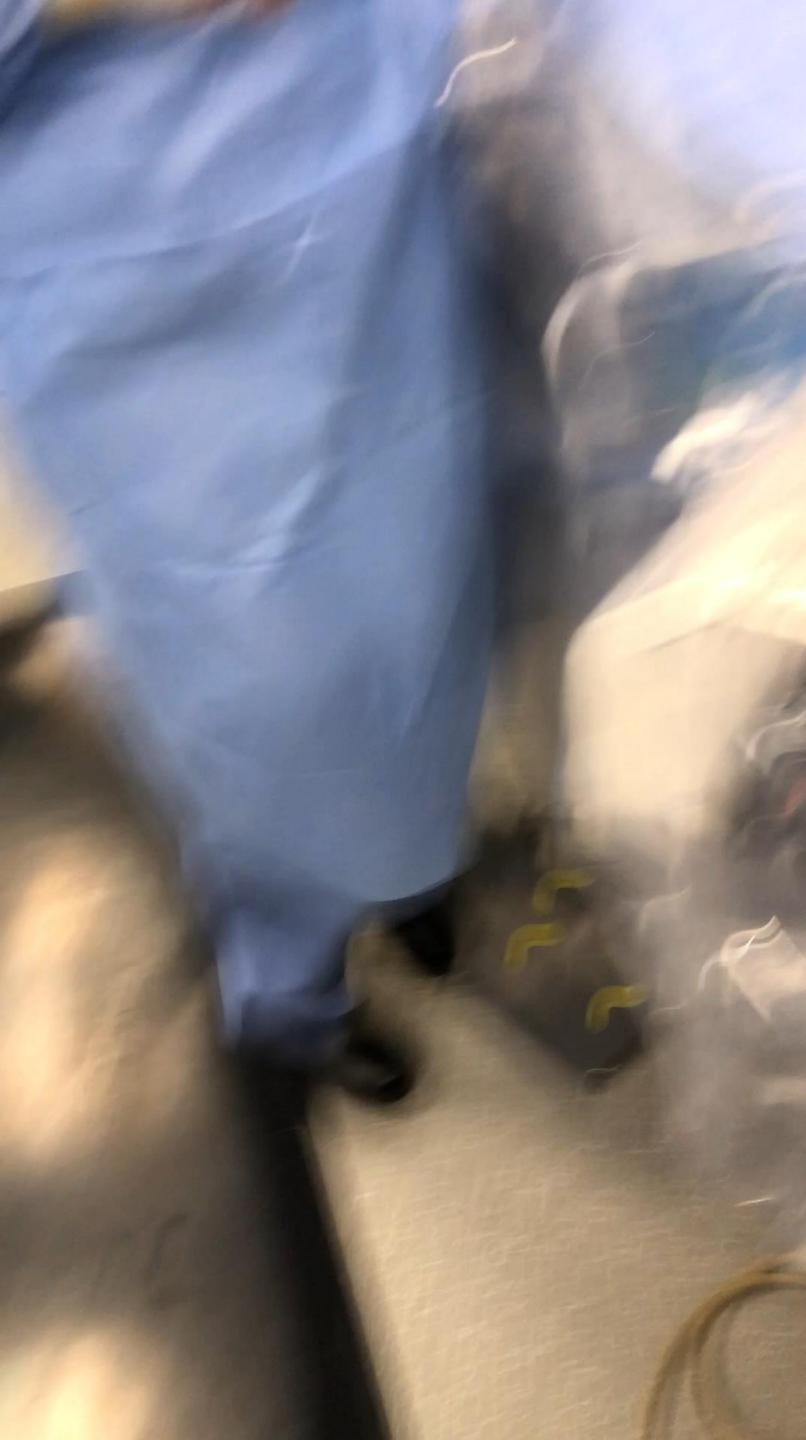

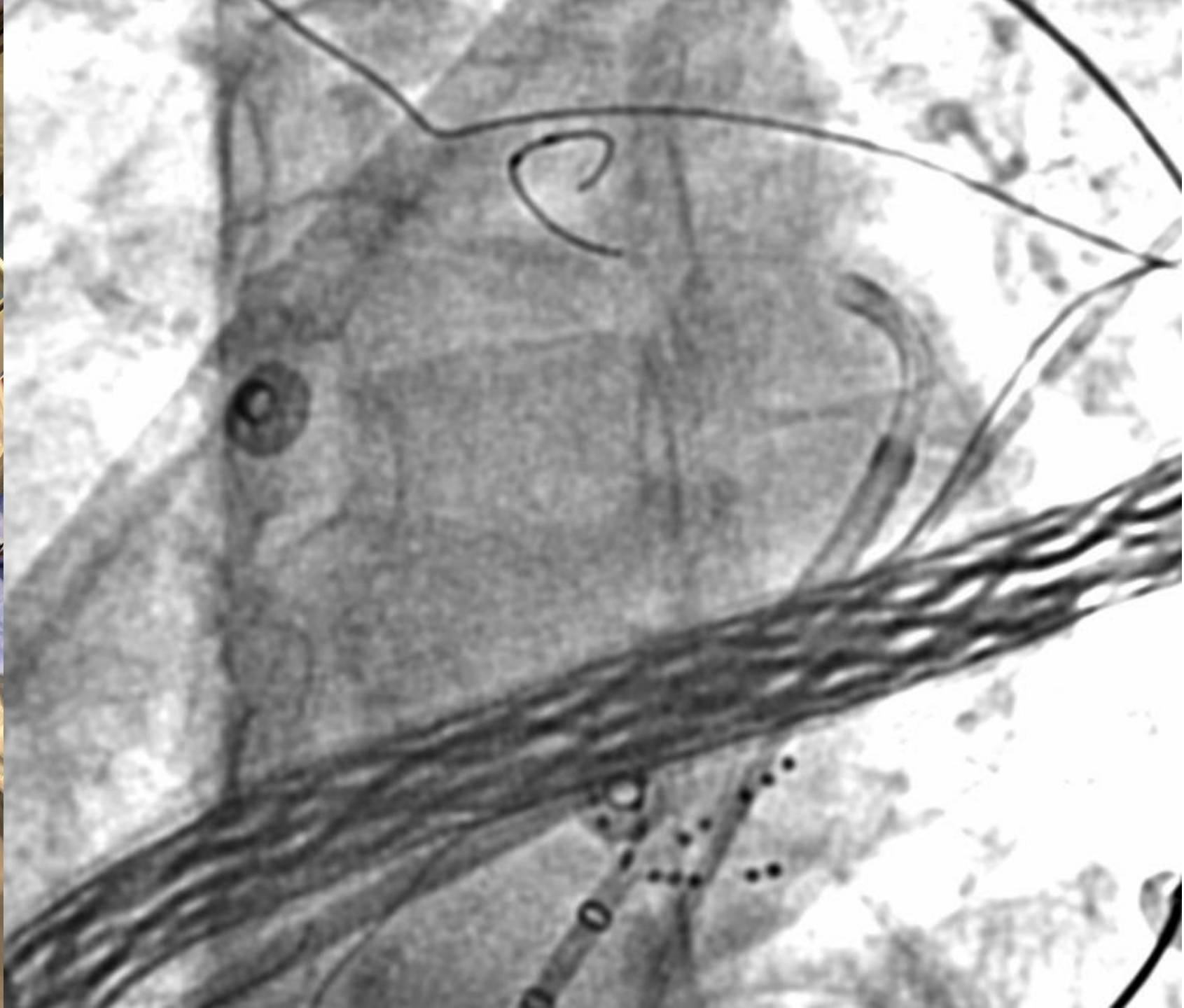
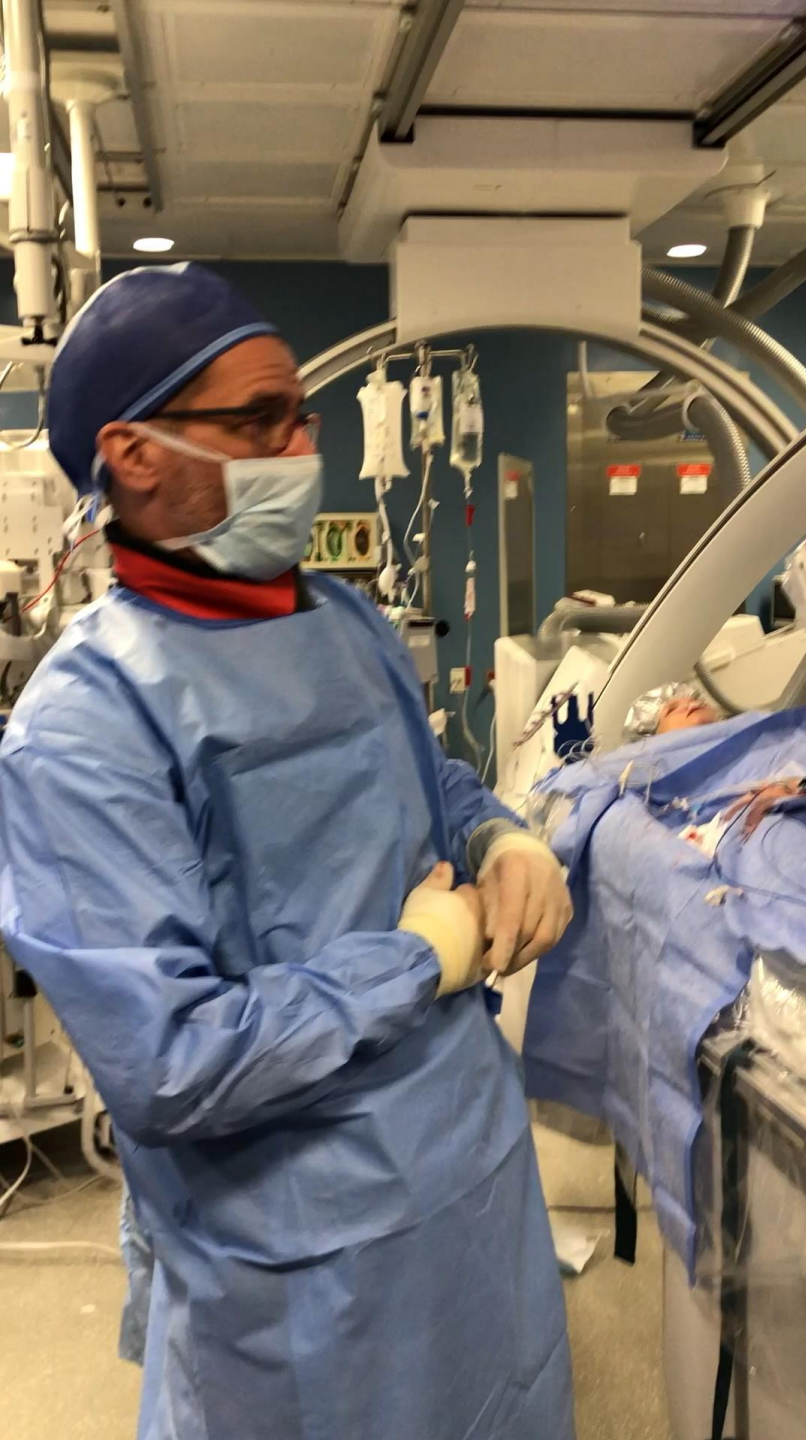Perfect pace-map from LV annular

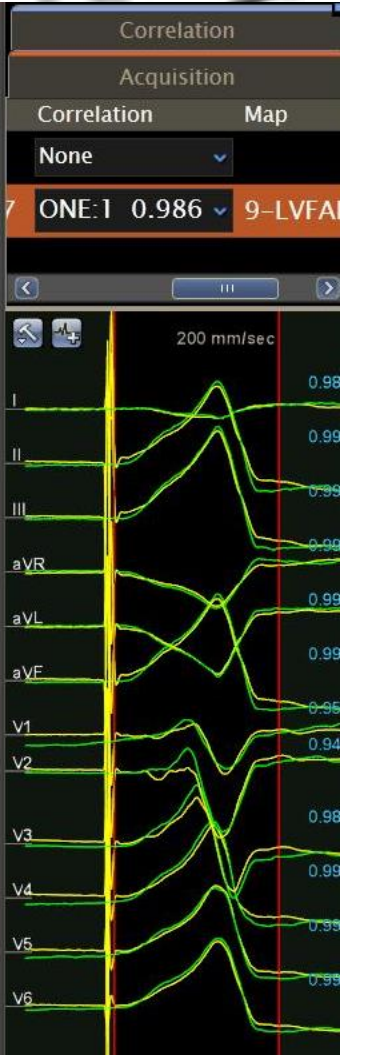
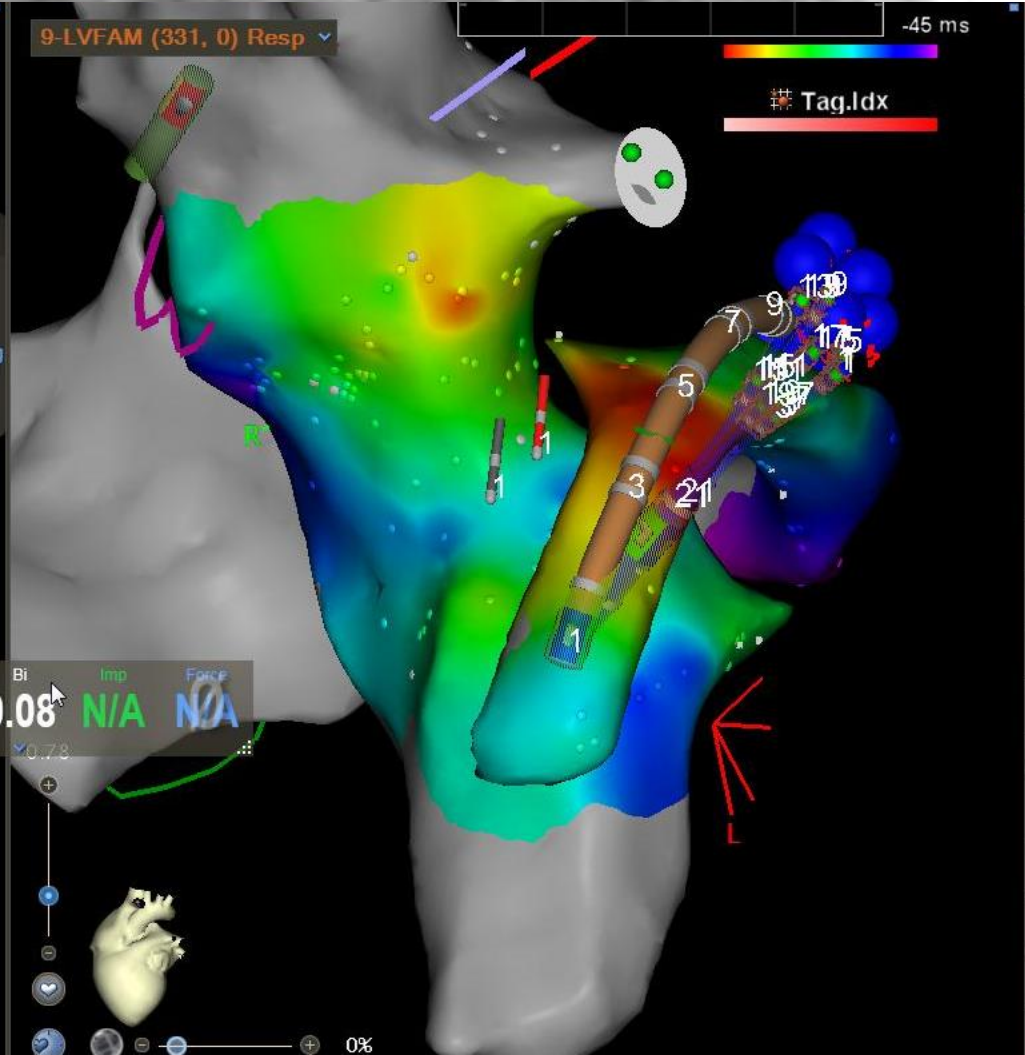
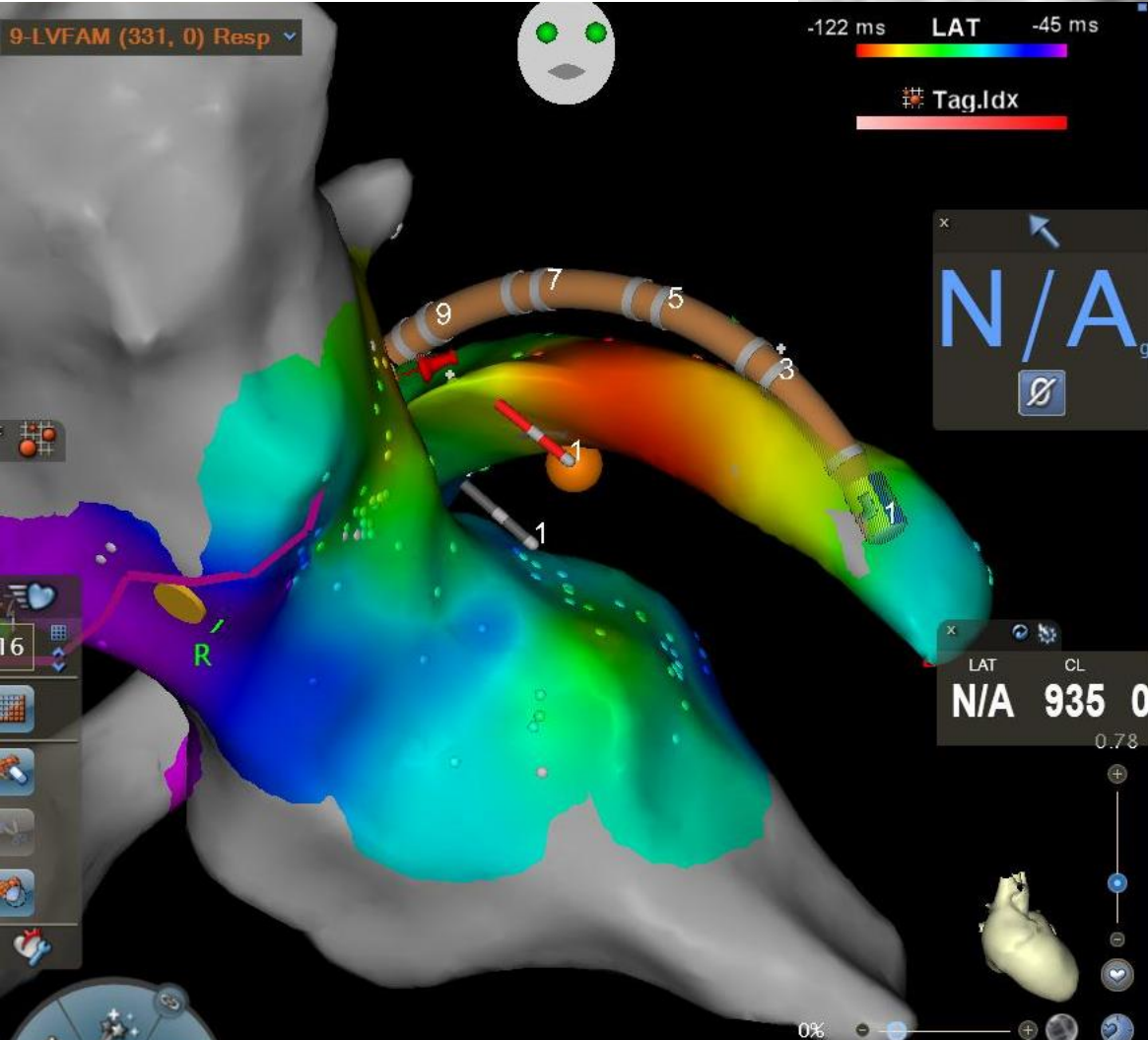
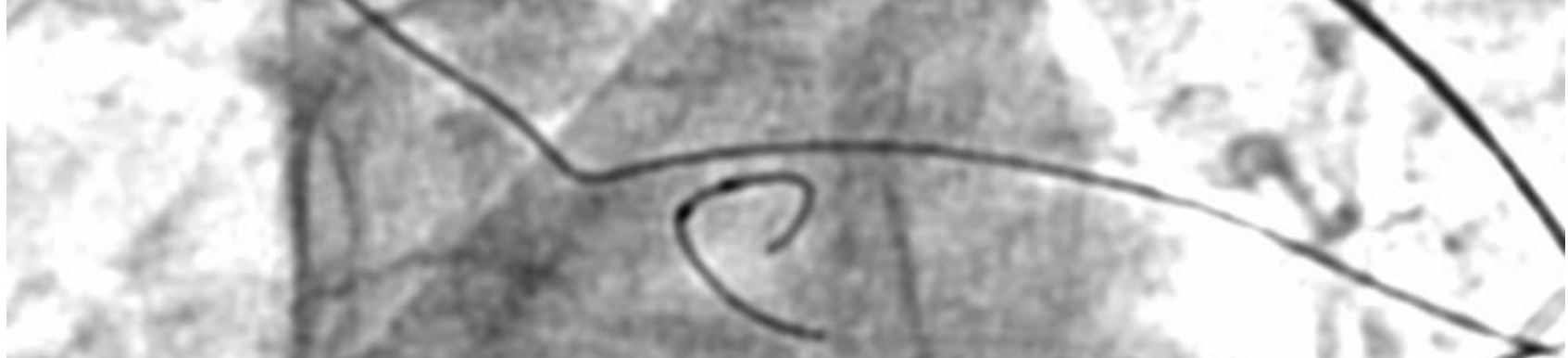

Branch of LV annular

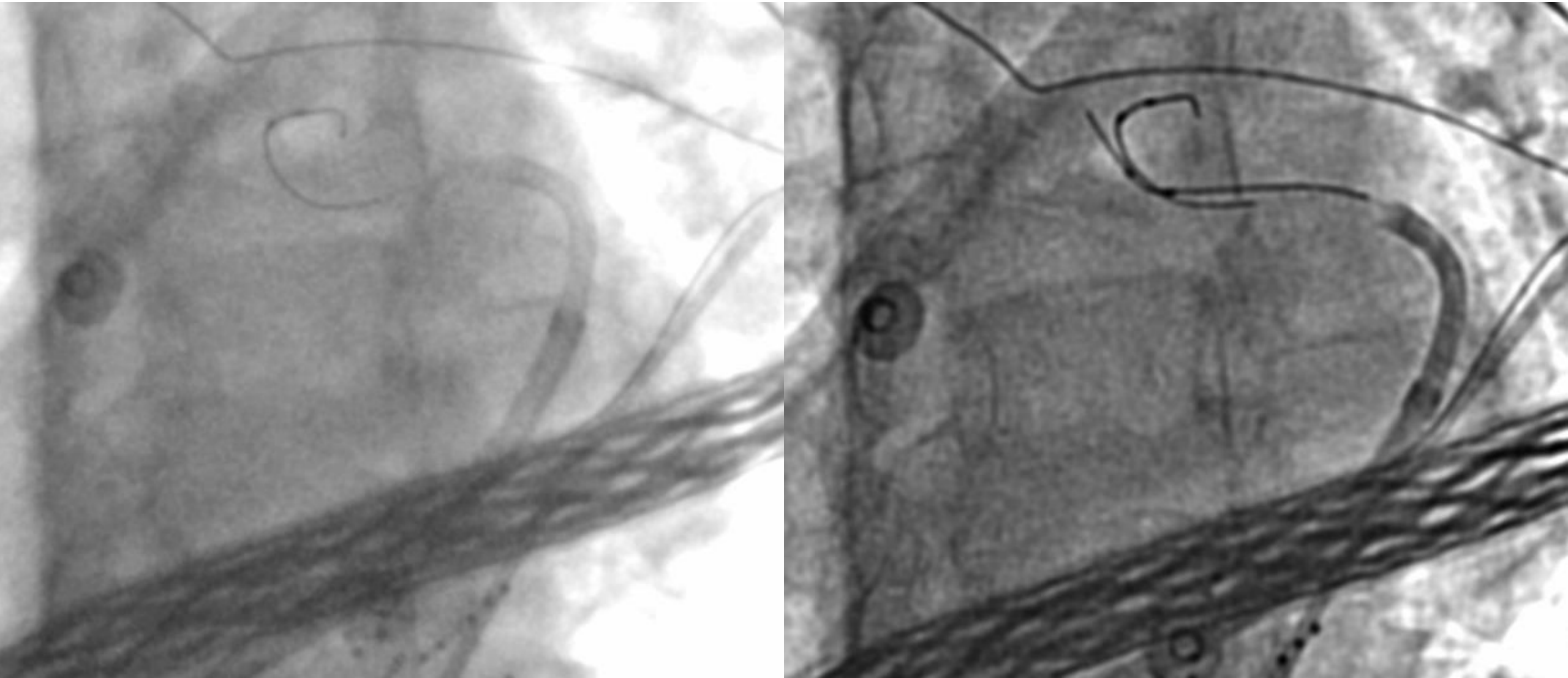




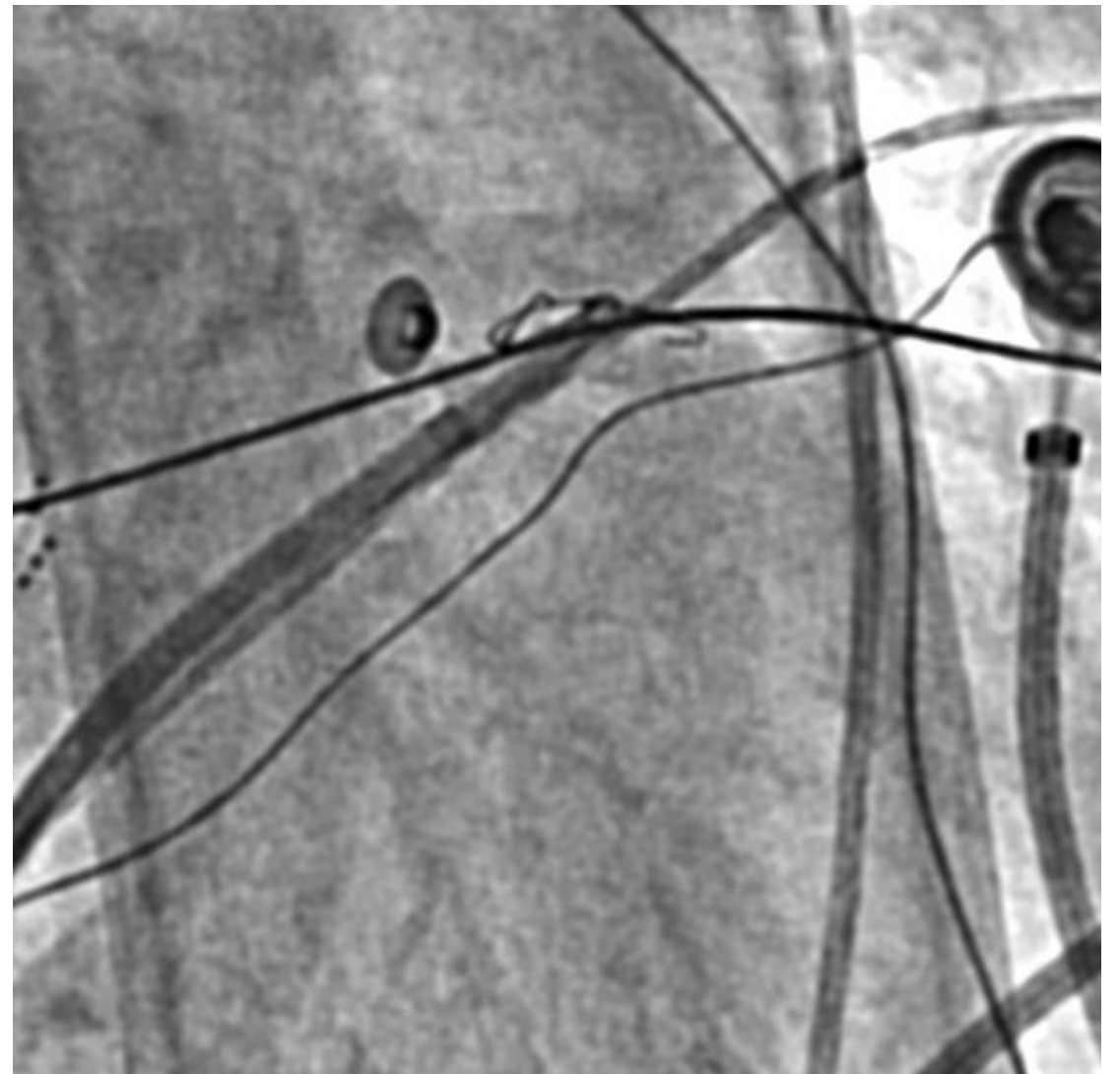
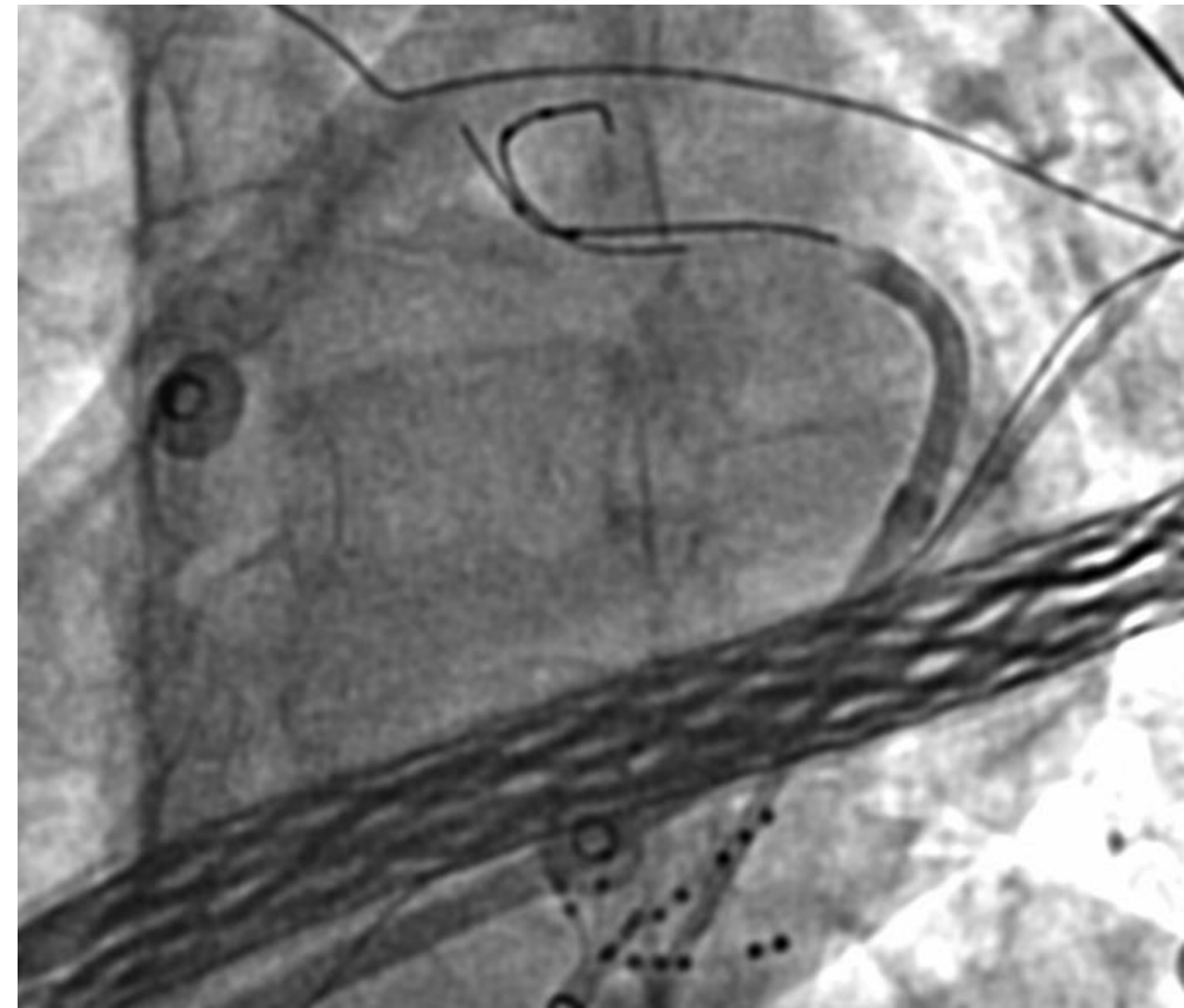




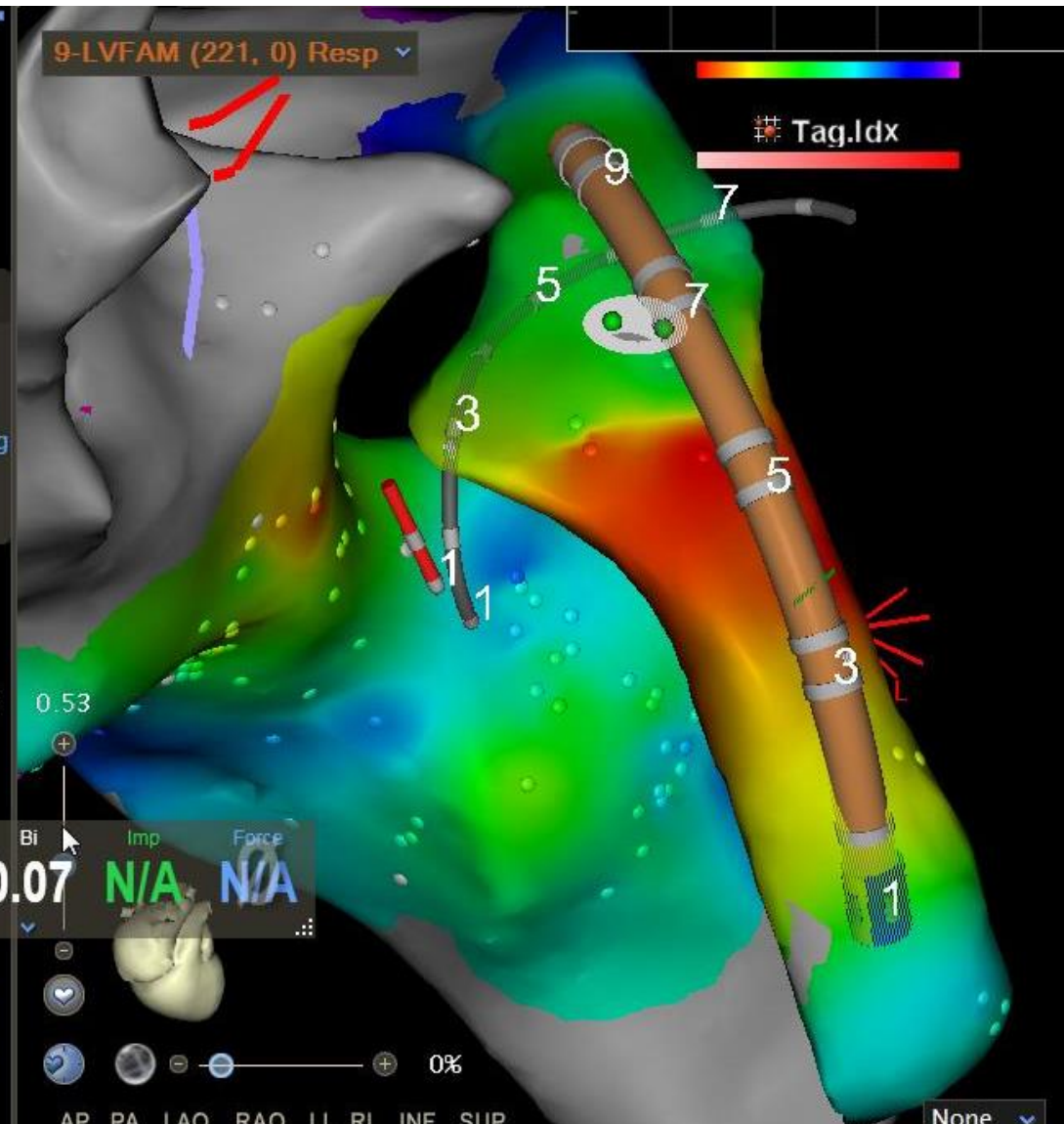
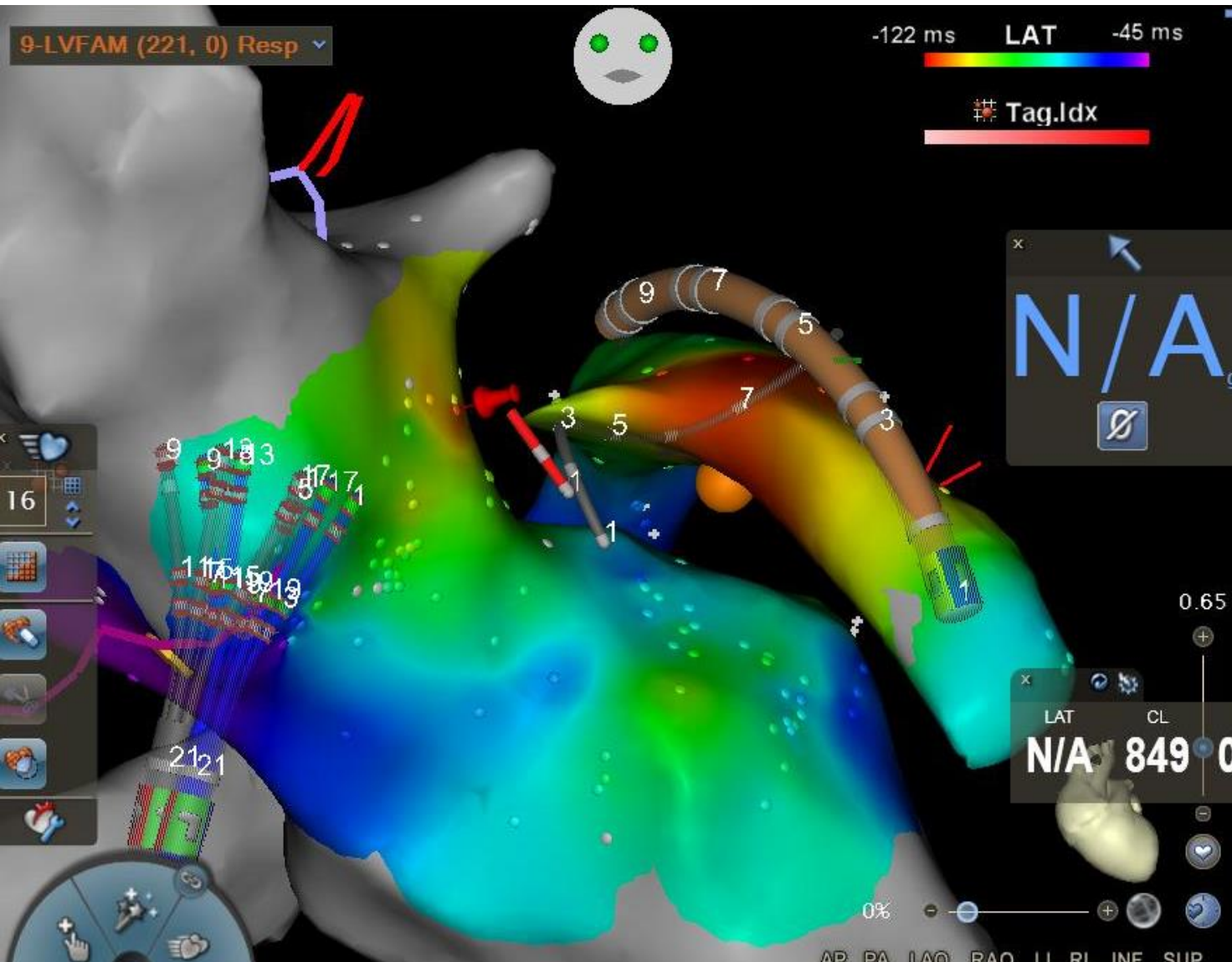
Double wiring and balloon



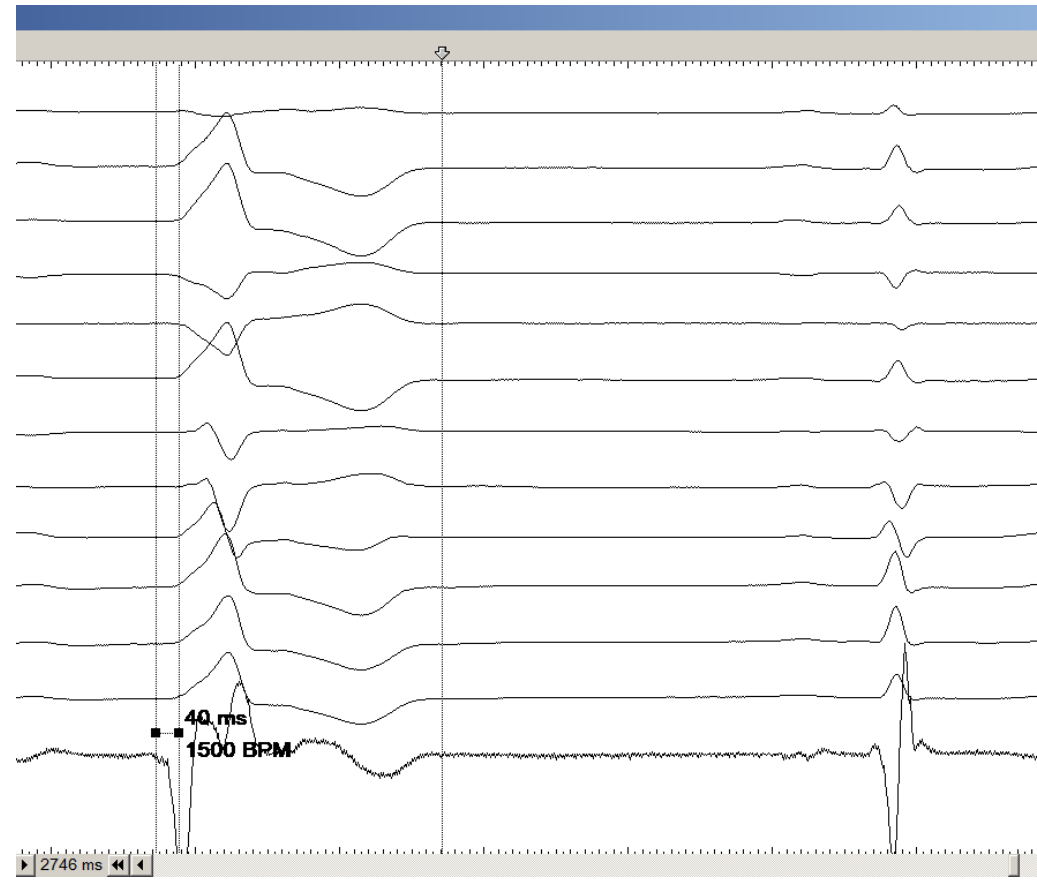
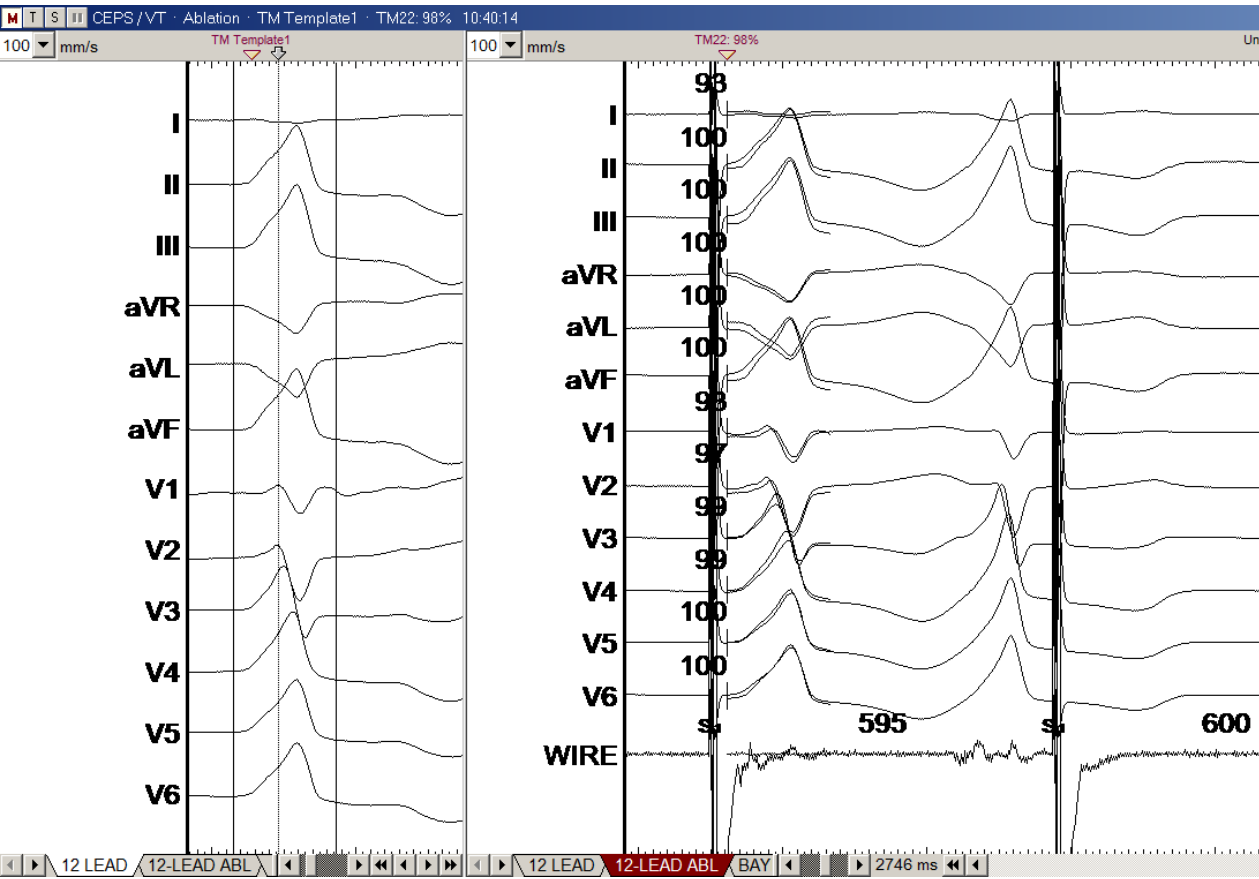
Double balloon-wire in LAO caudal vs RAO



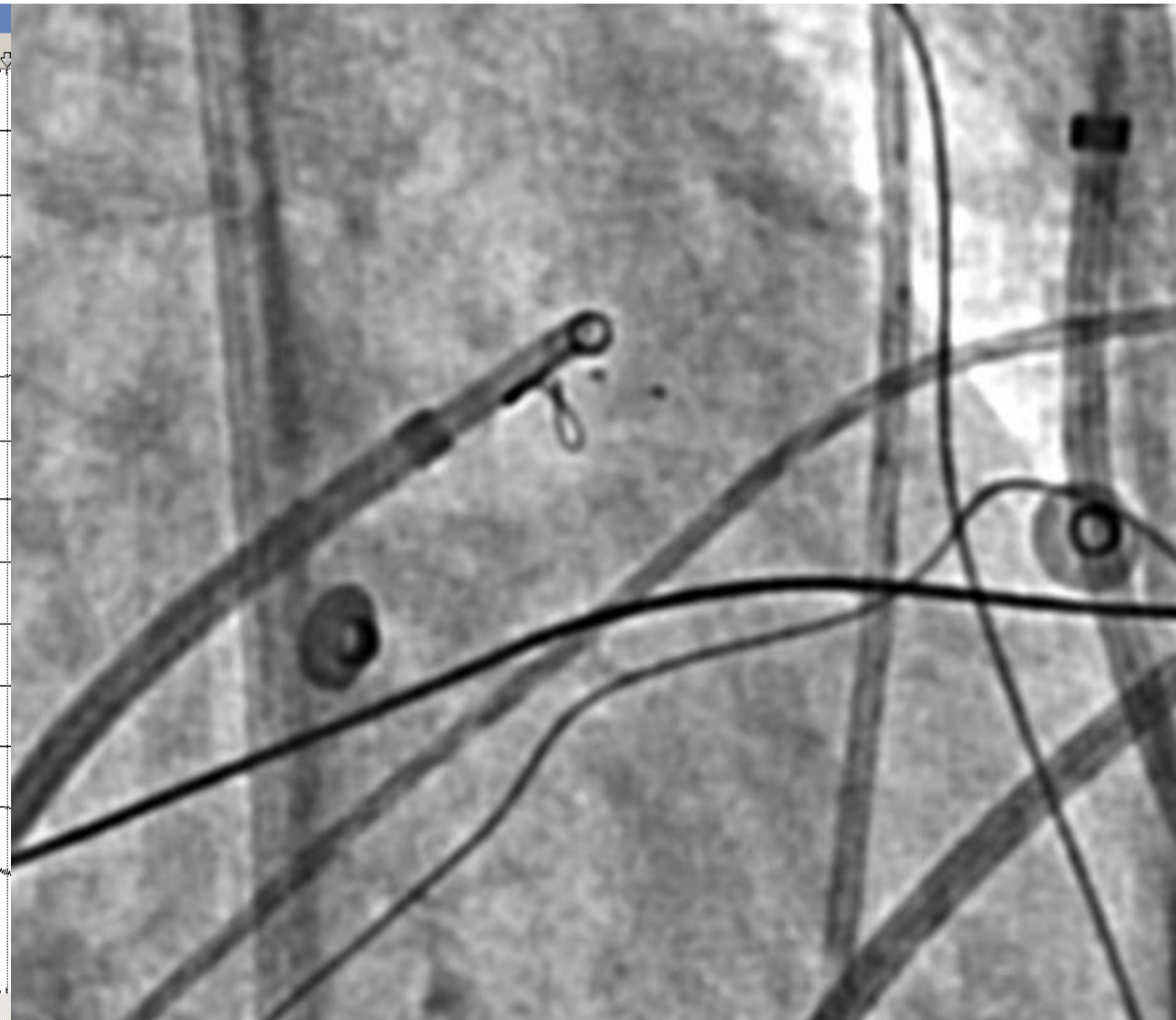
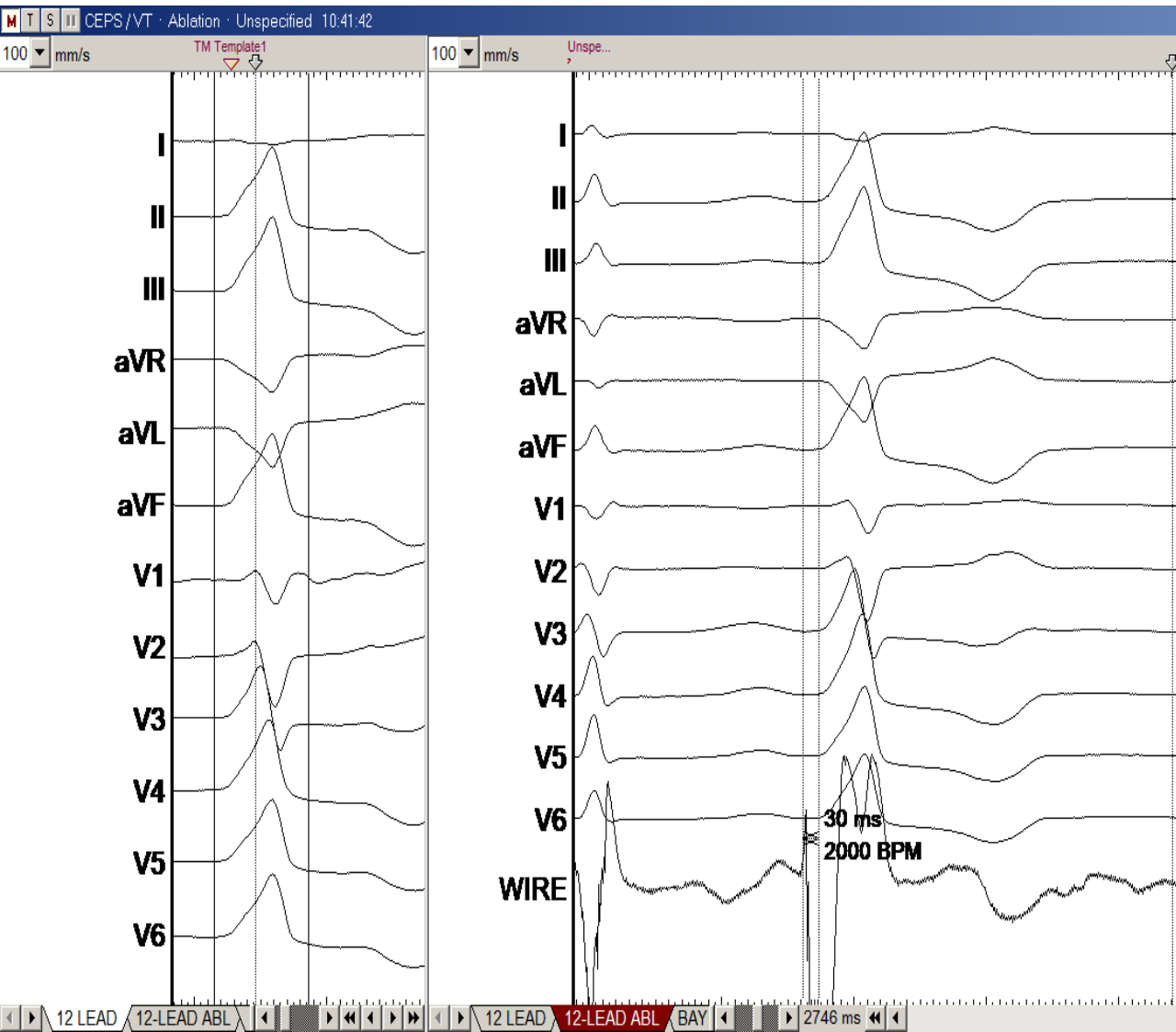
Proximal Wire placement vs EP Star placement

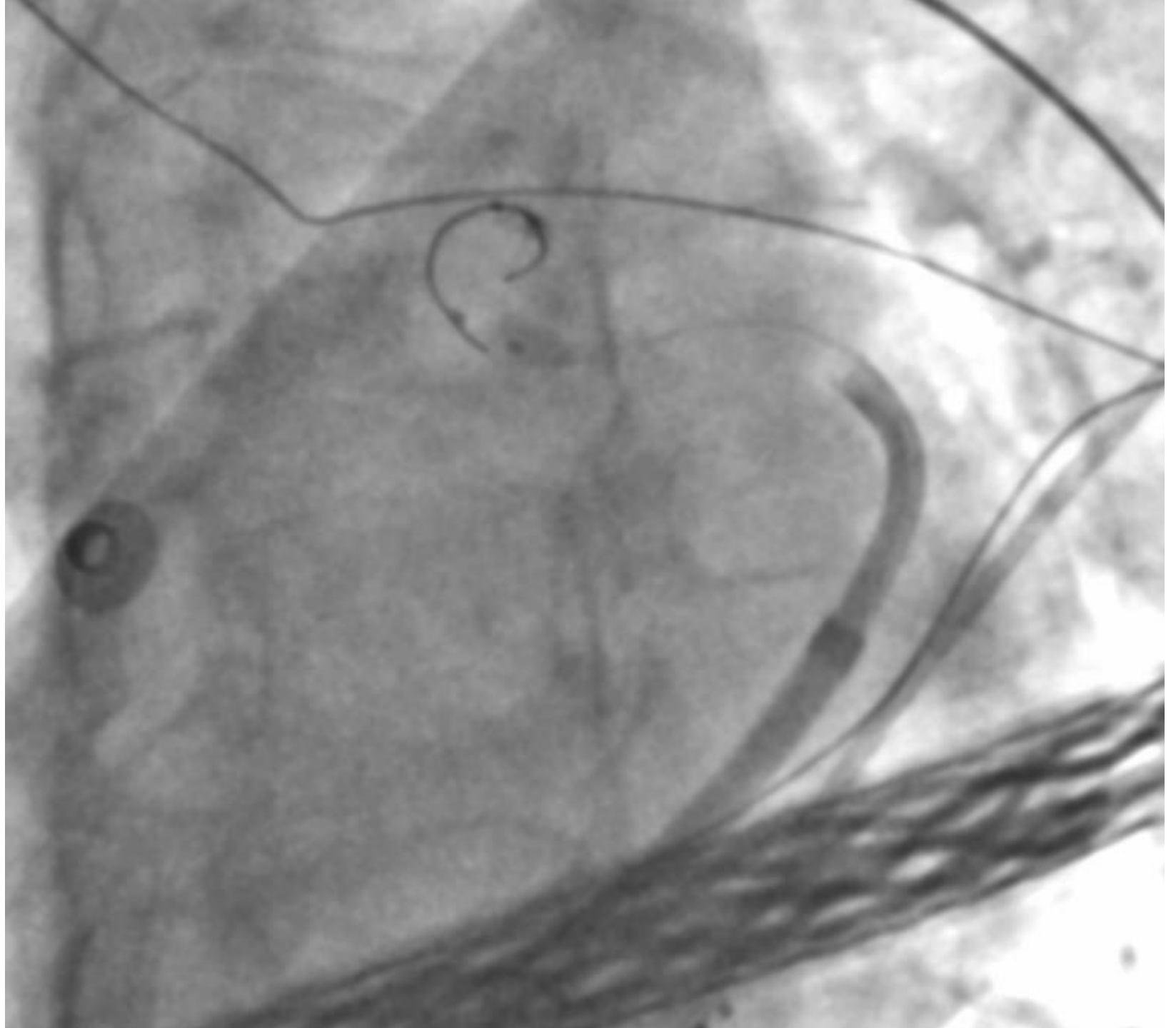
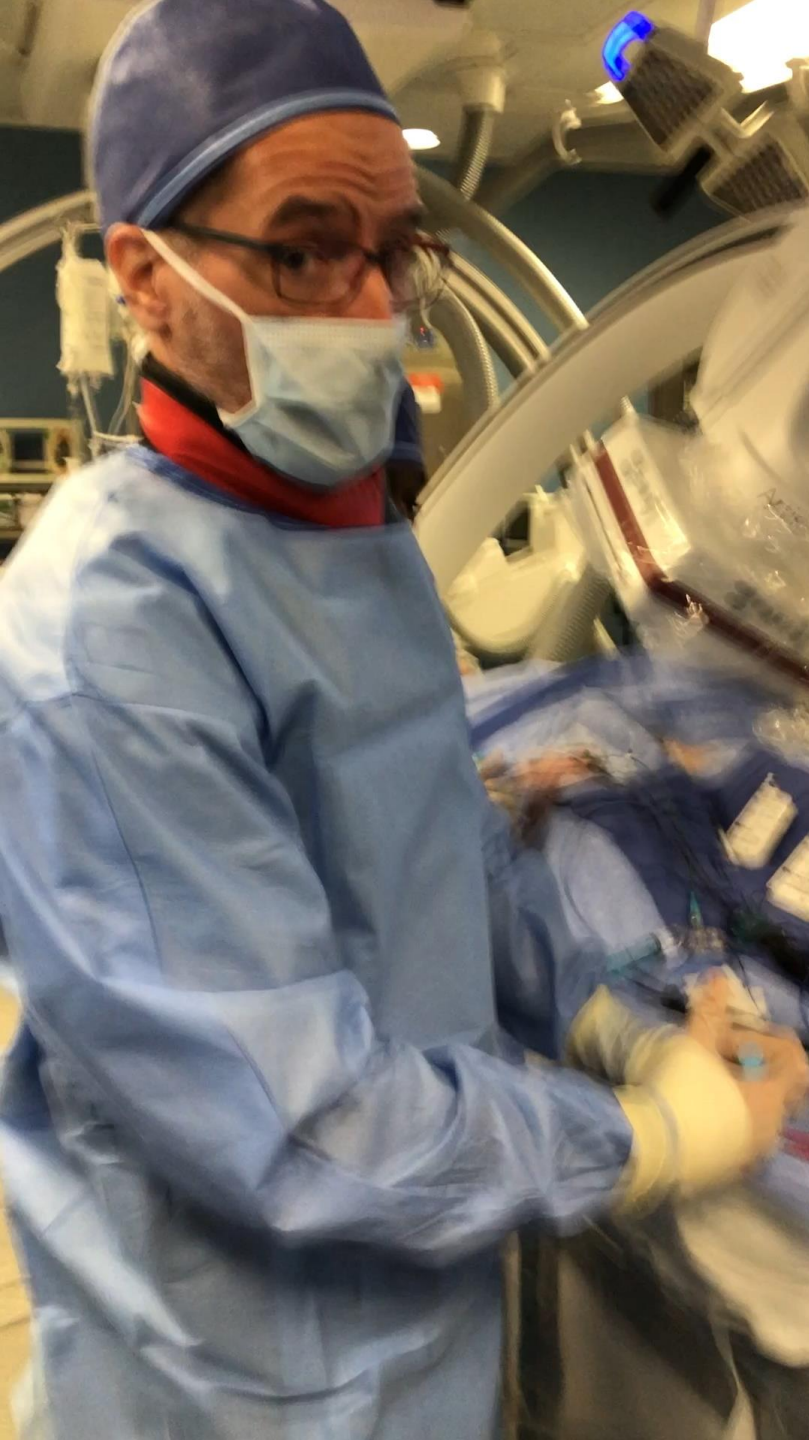

Proximal WIRE signal and pace-map

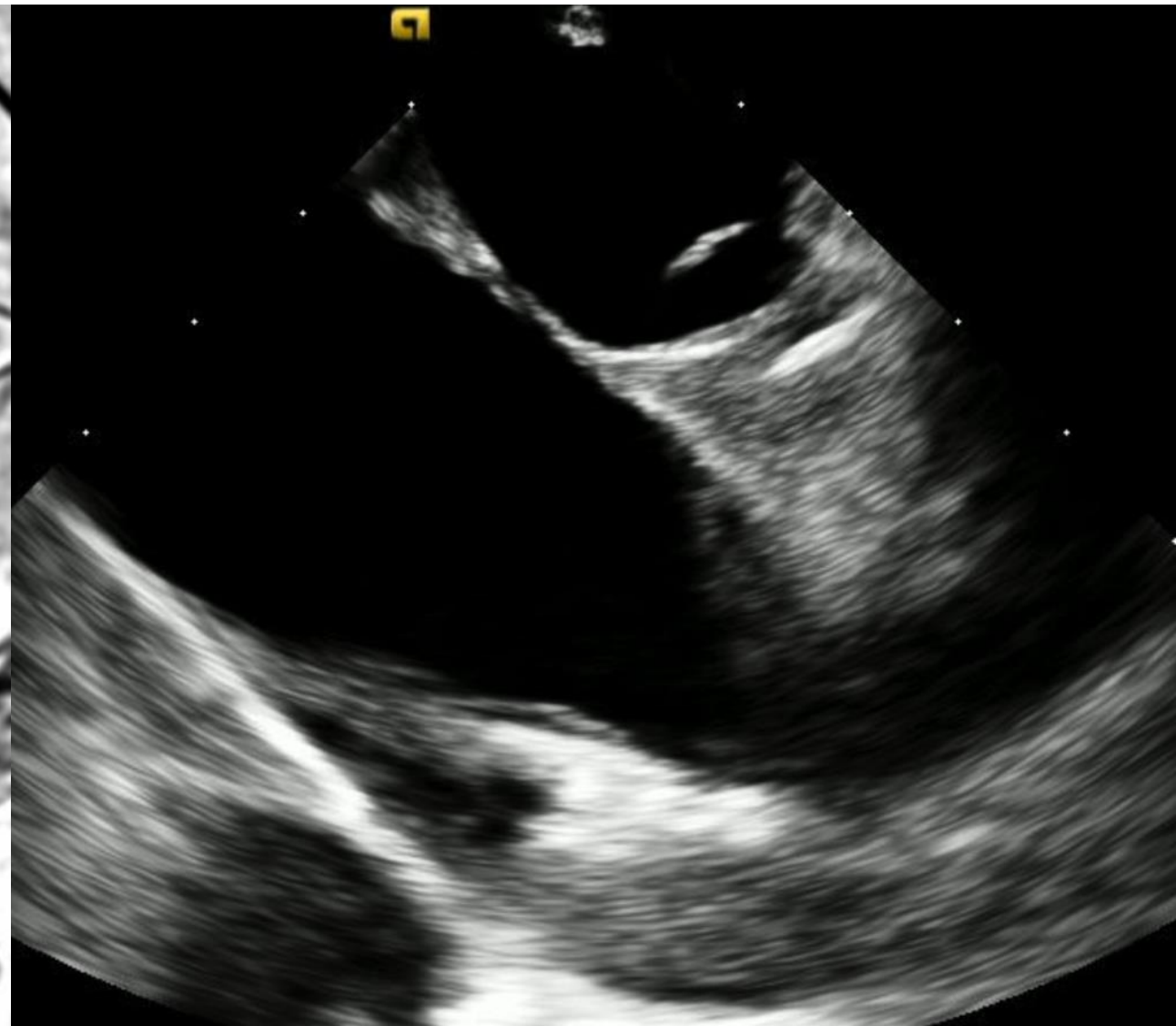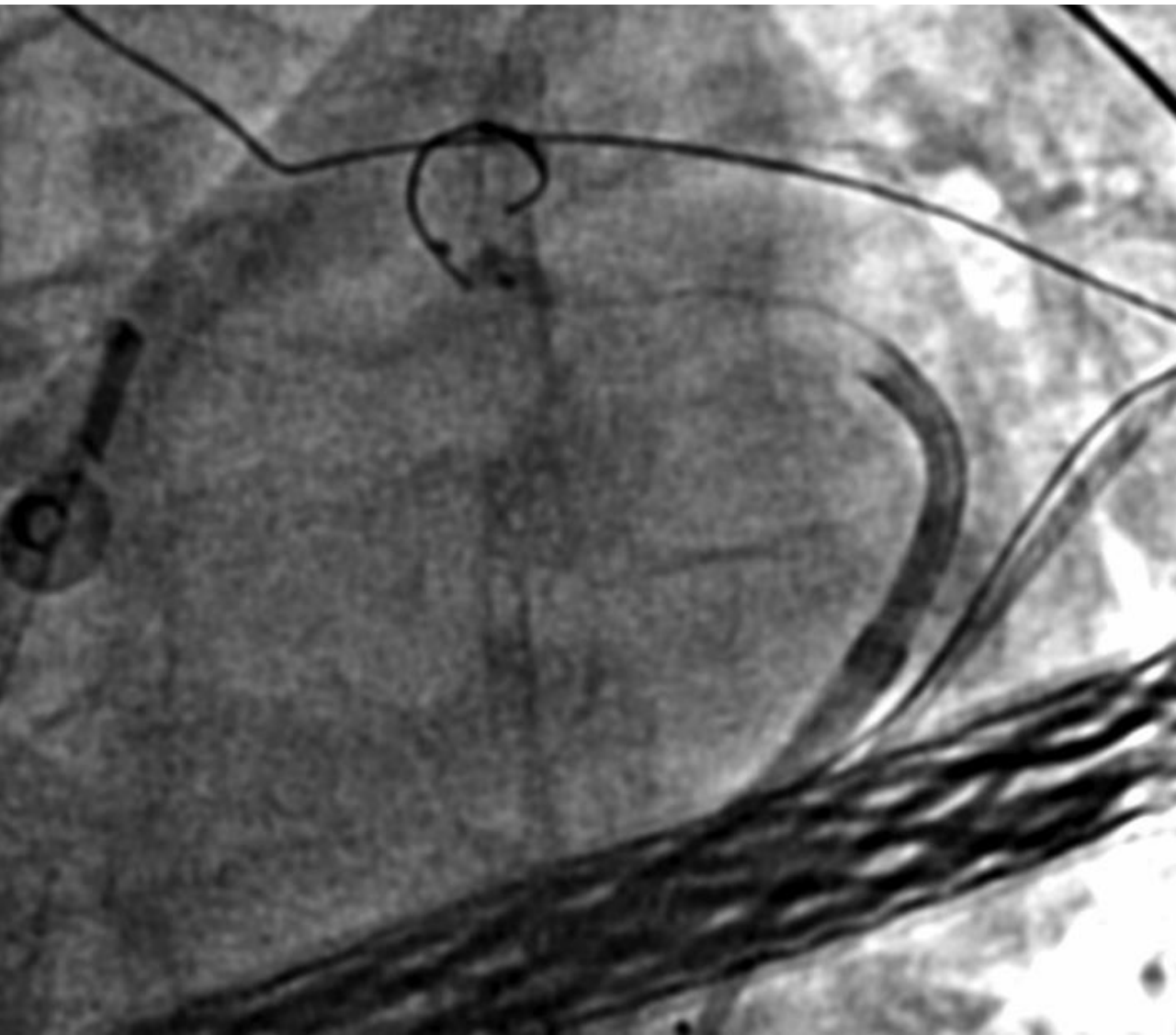


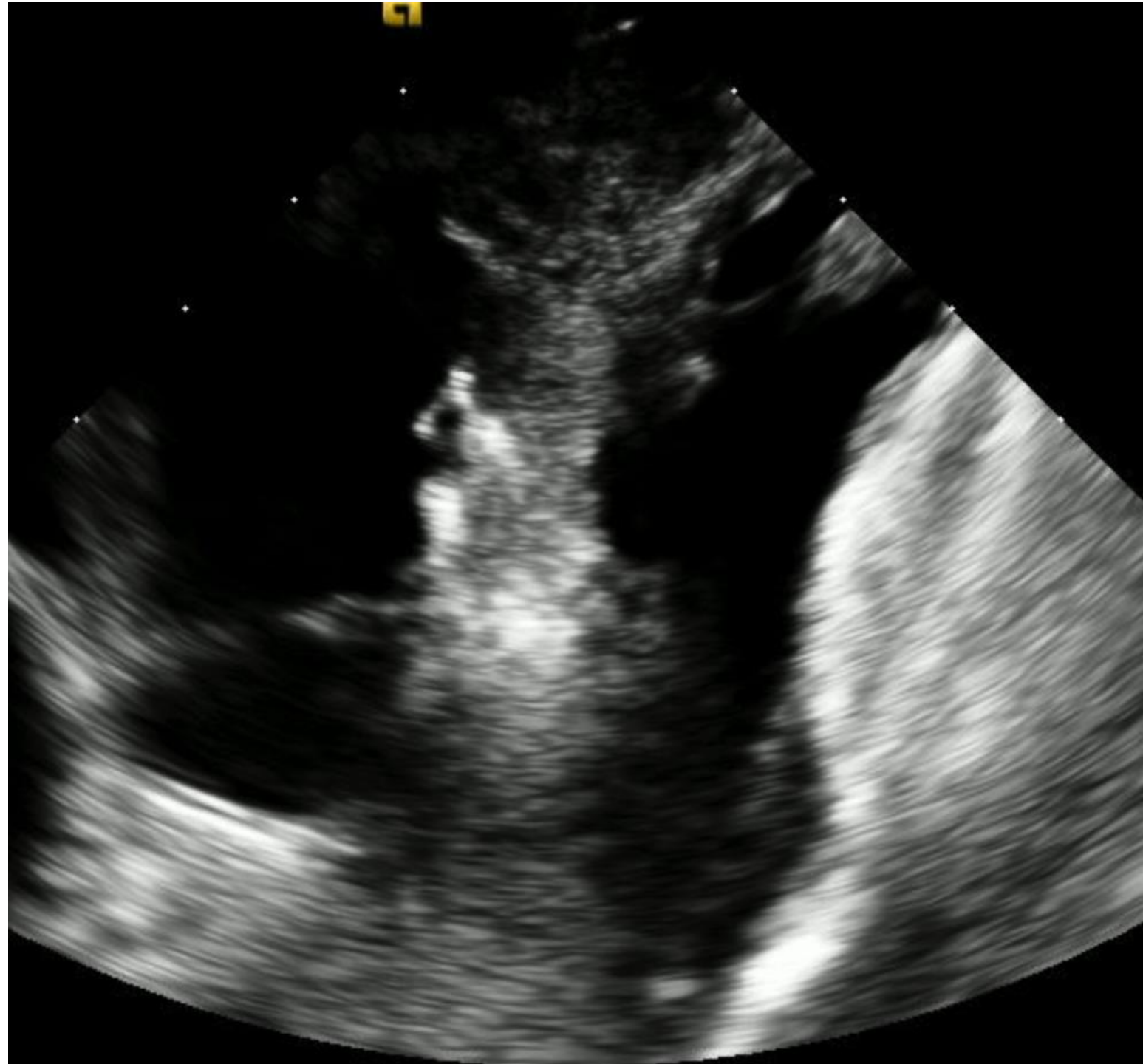
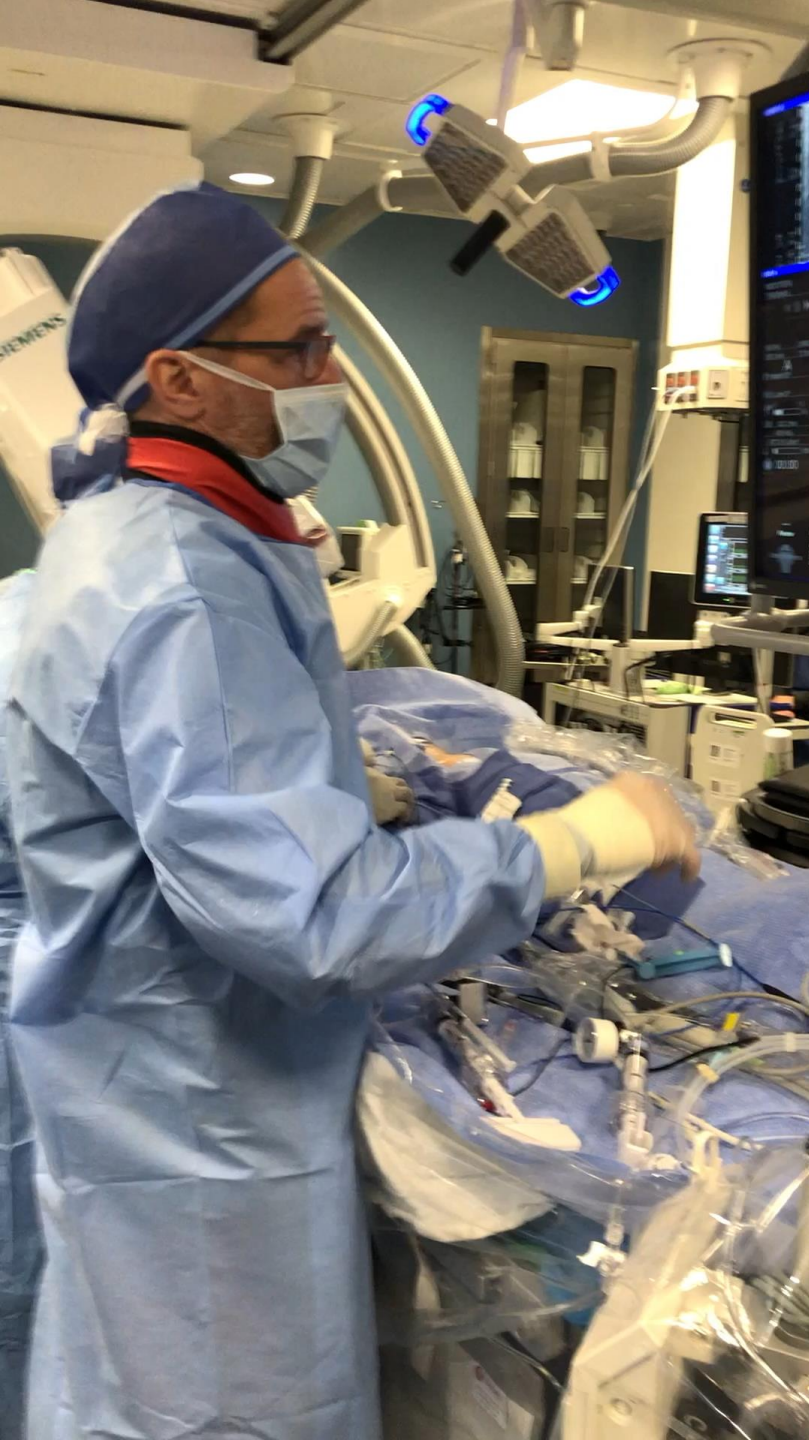Distal WIRE signal and vein



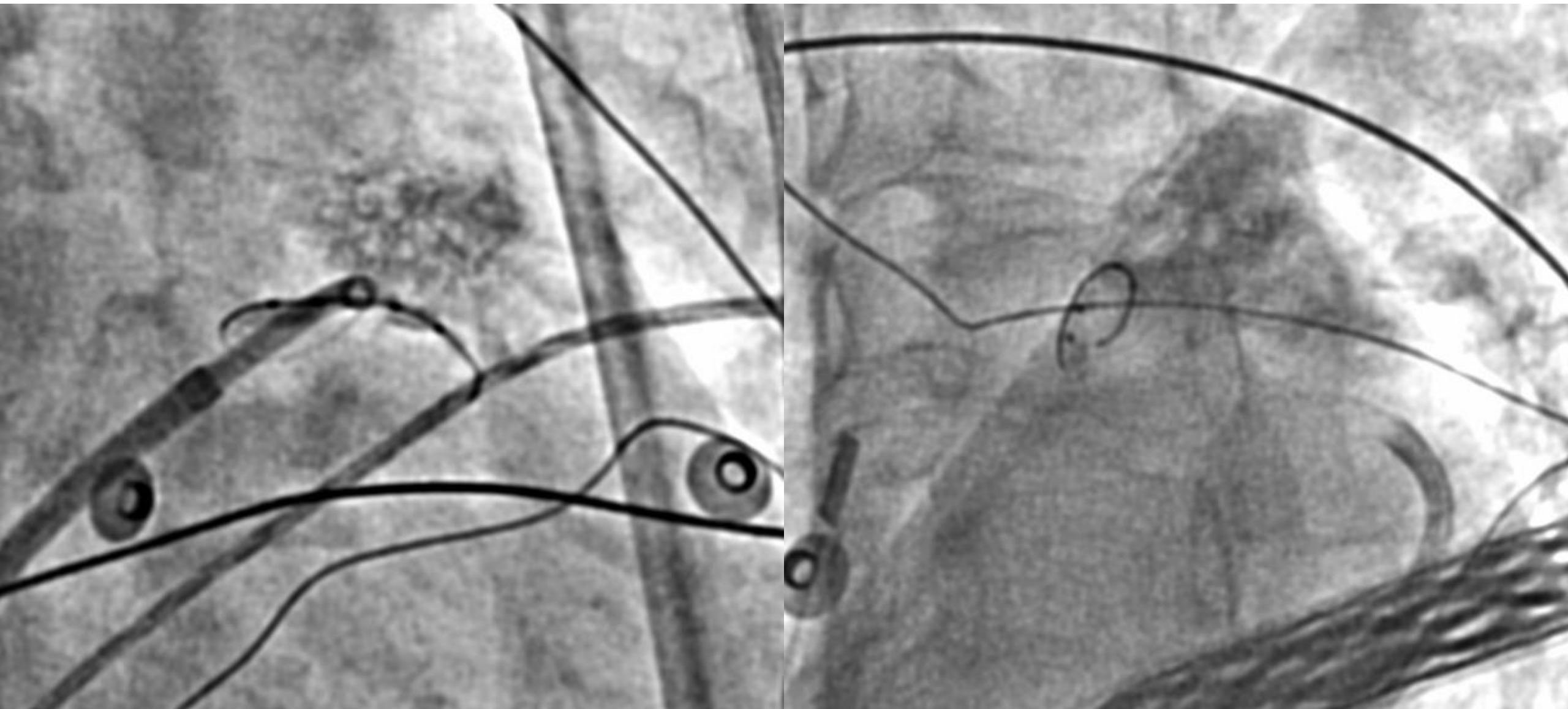


Ethanol injection

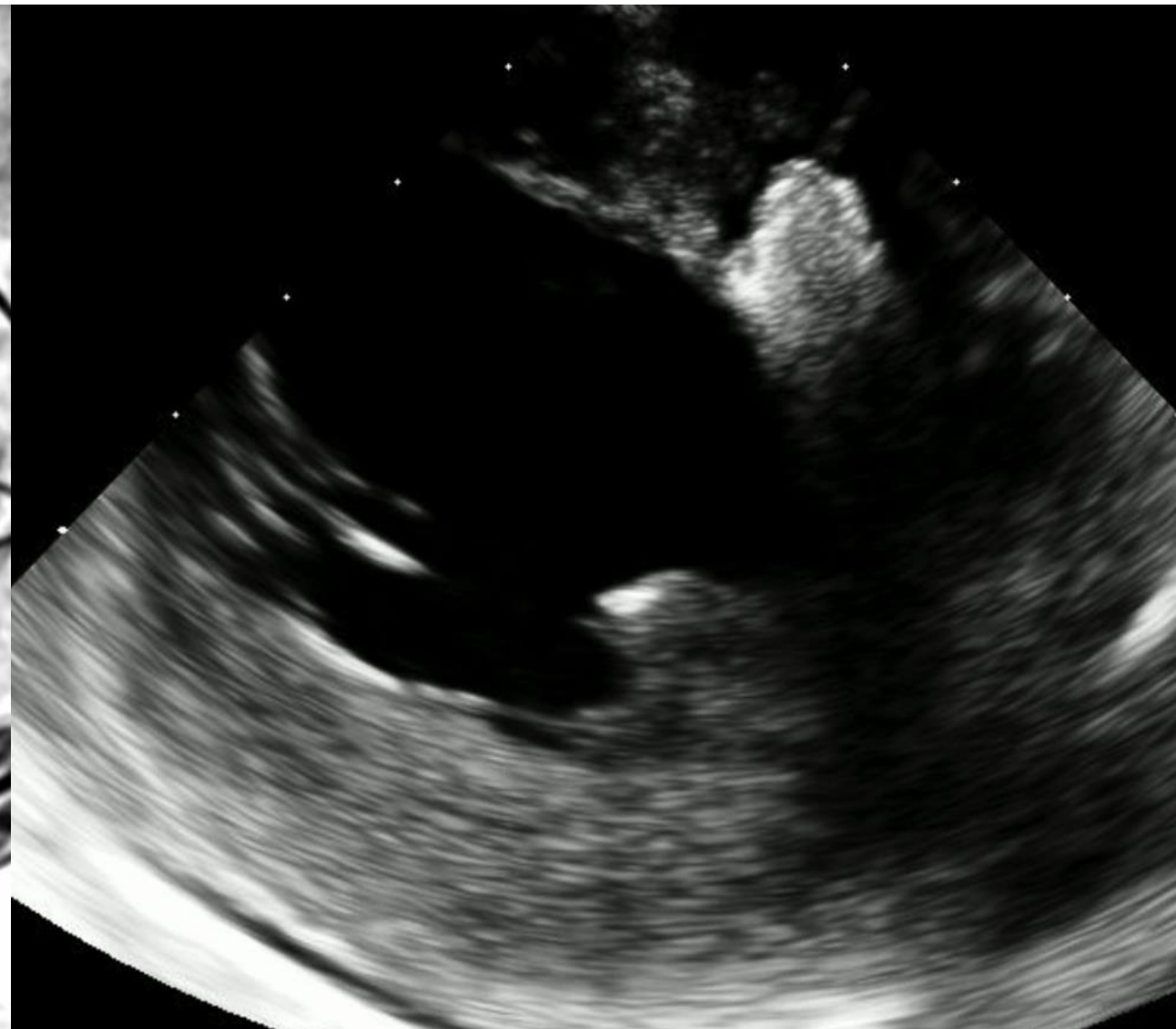
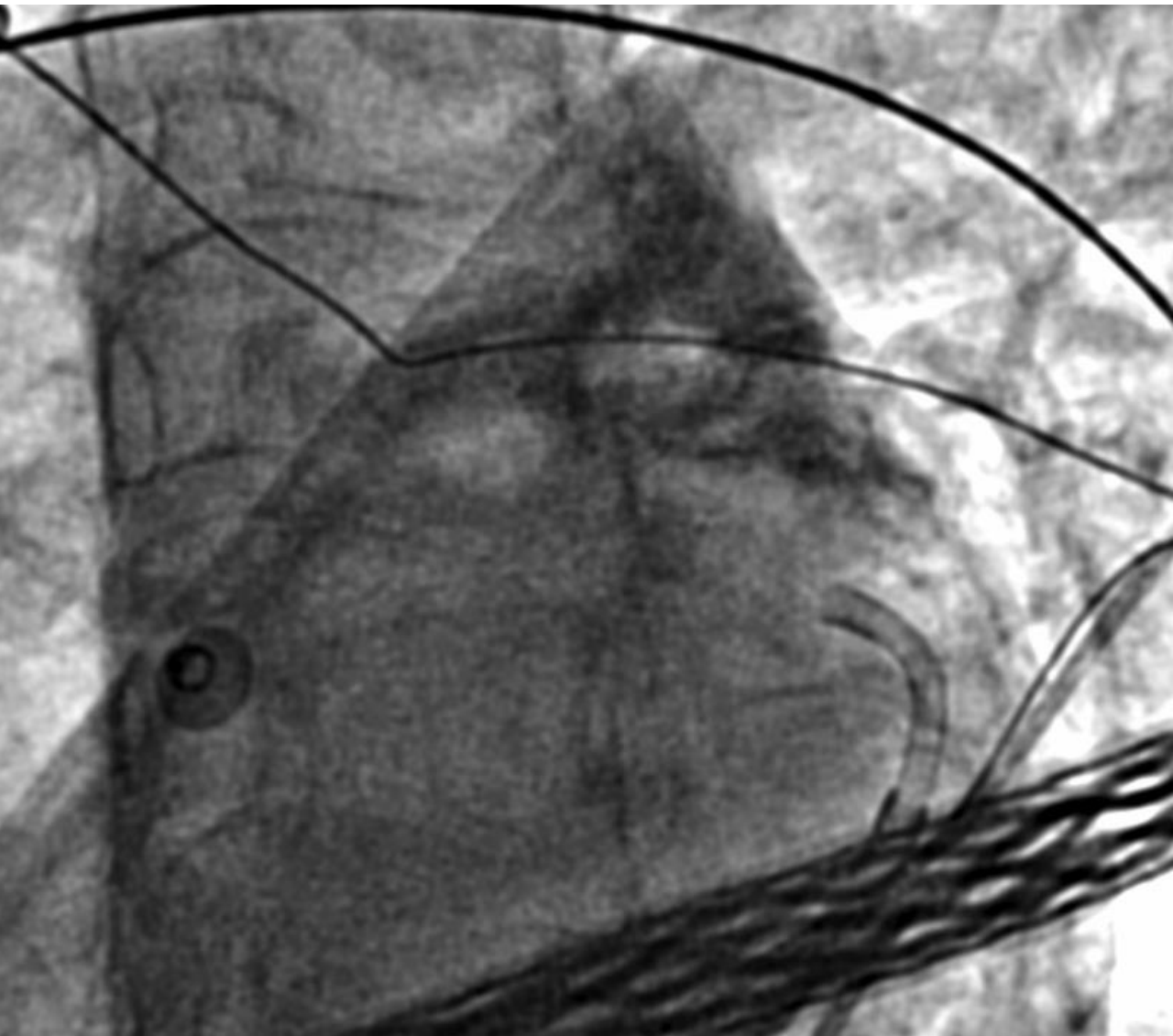




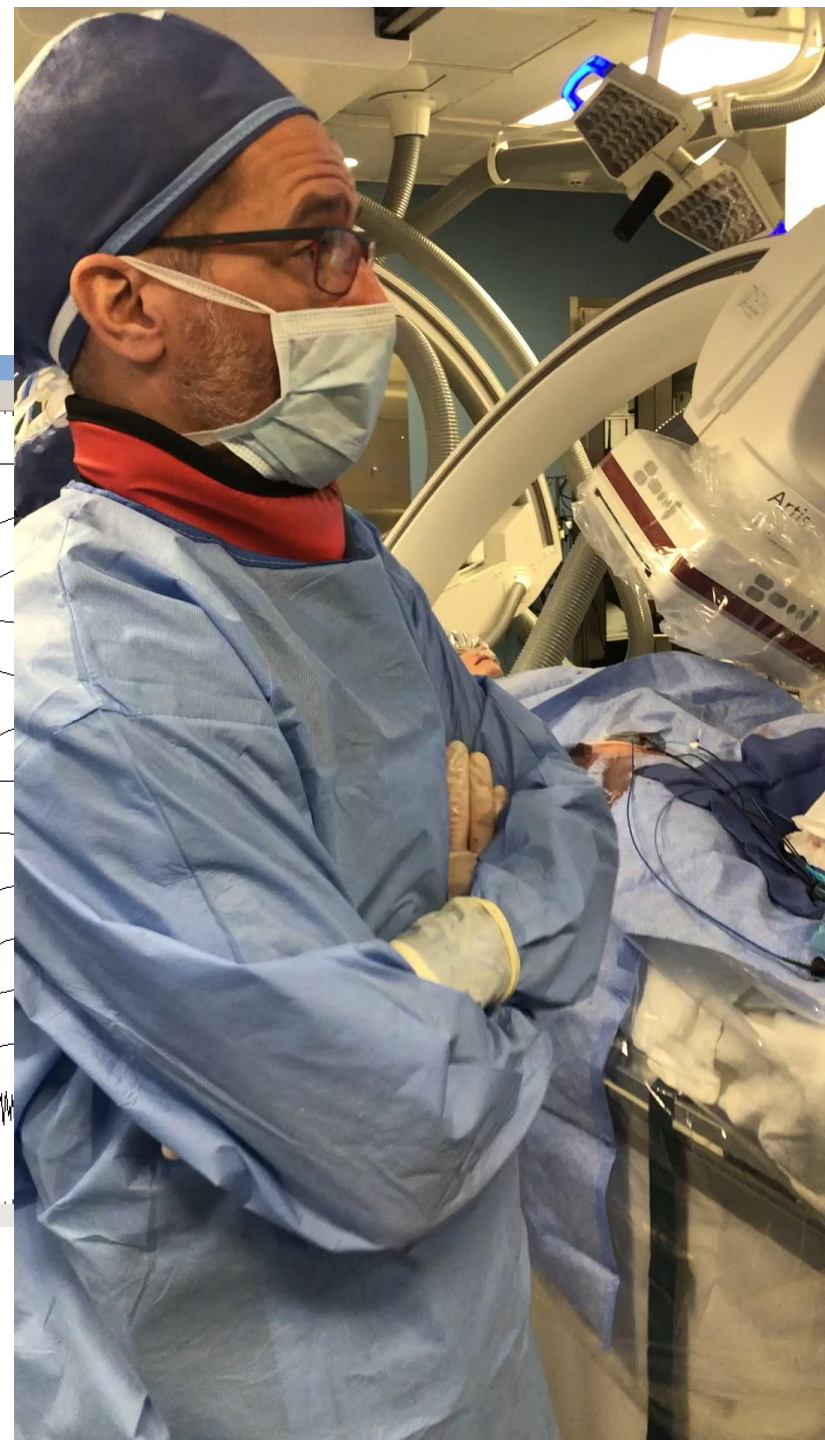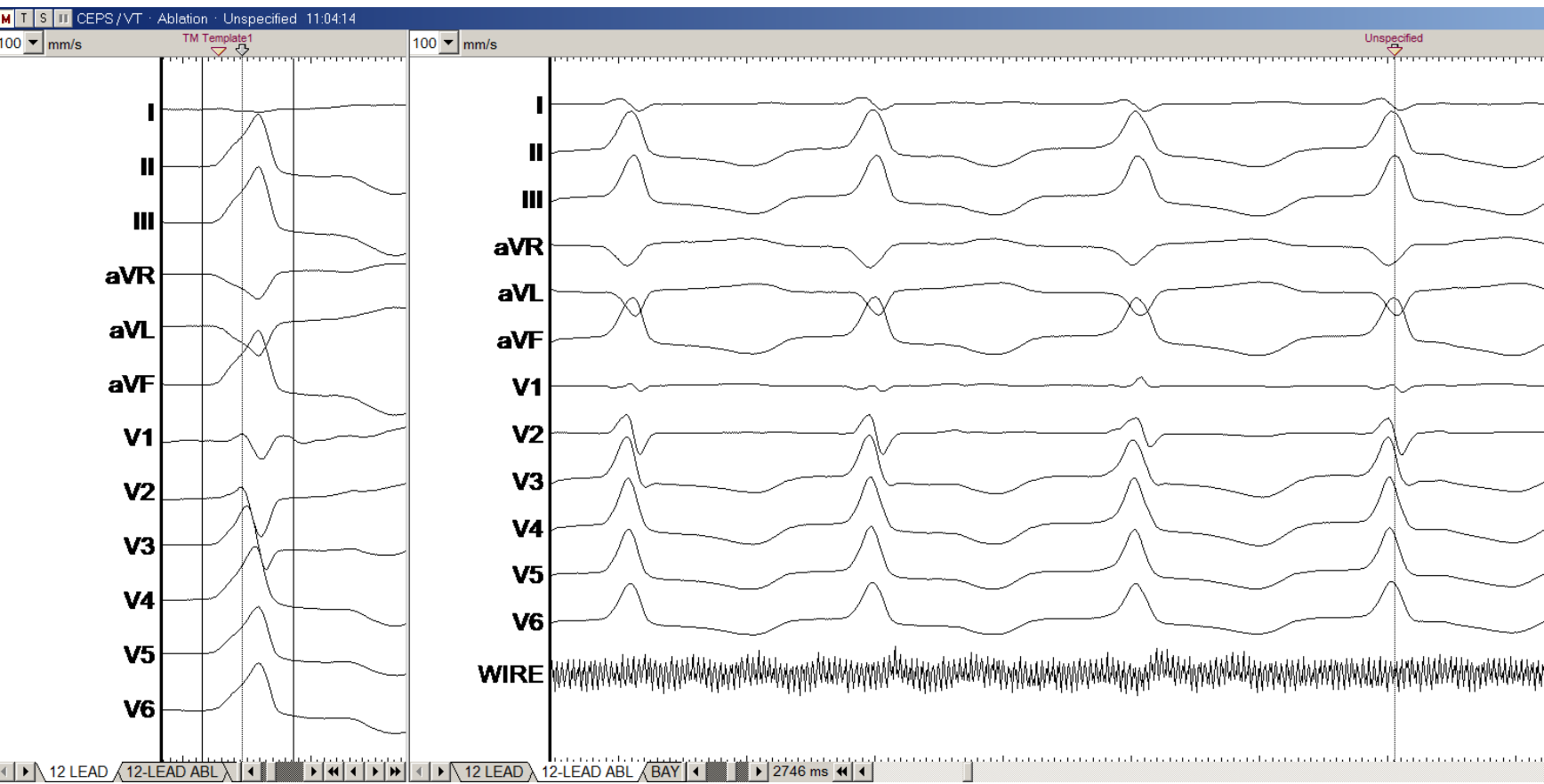
Ethanol injection



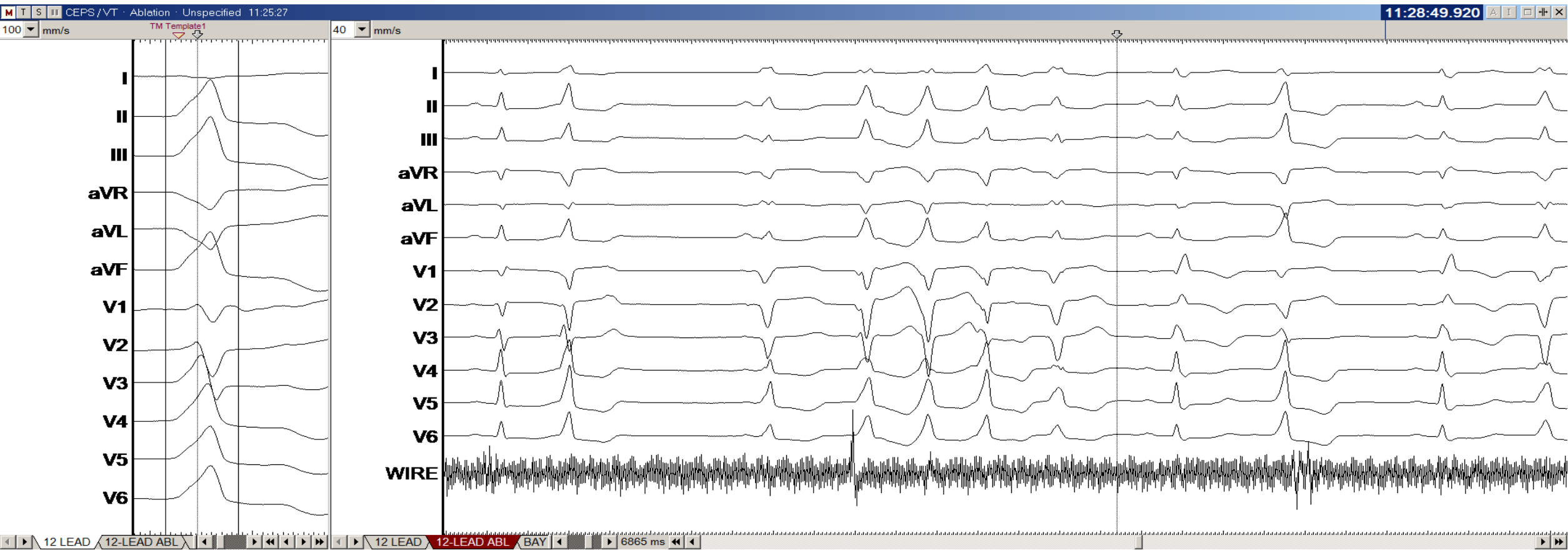
Ethanol injection



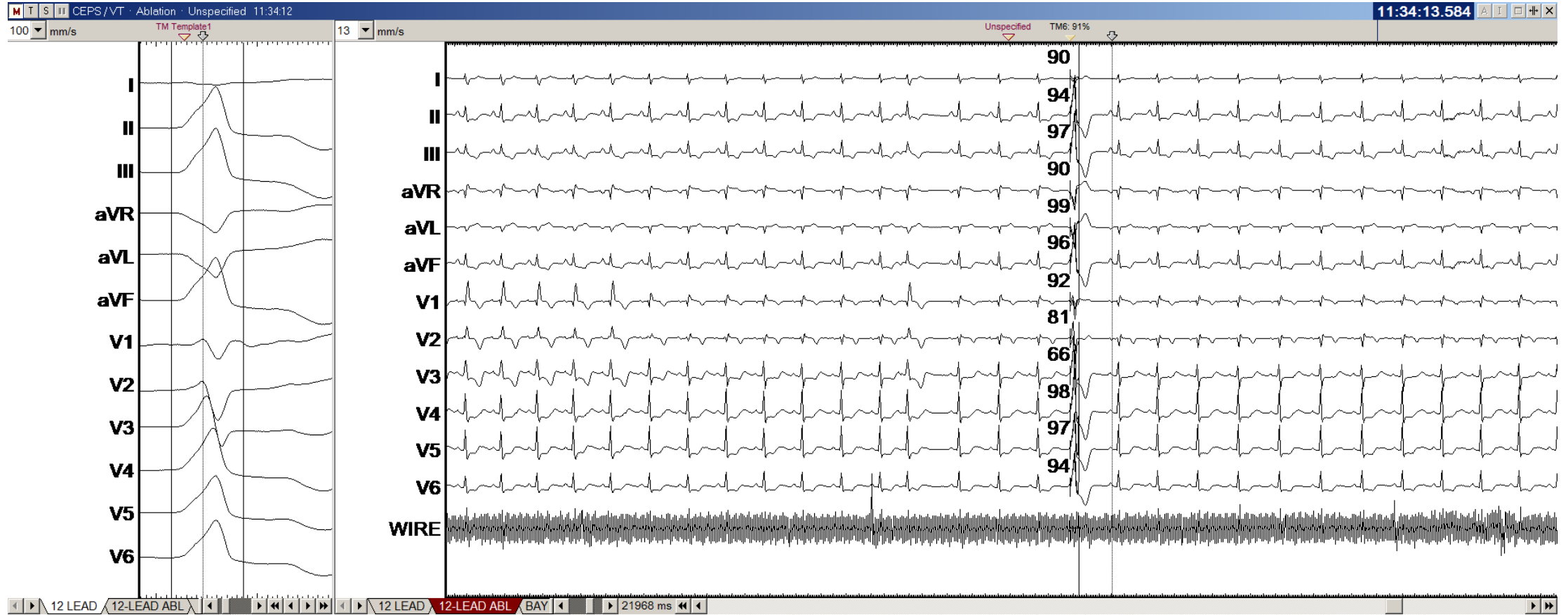
Ethanol-induced VT



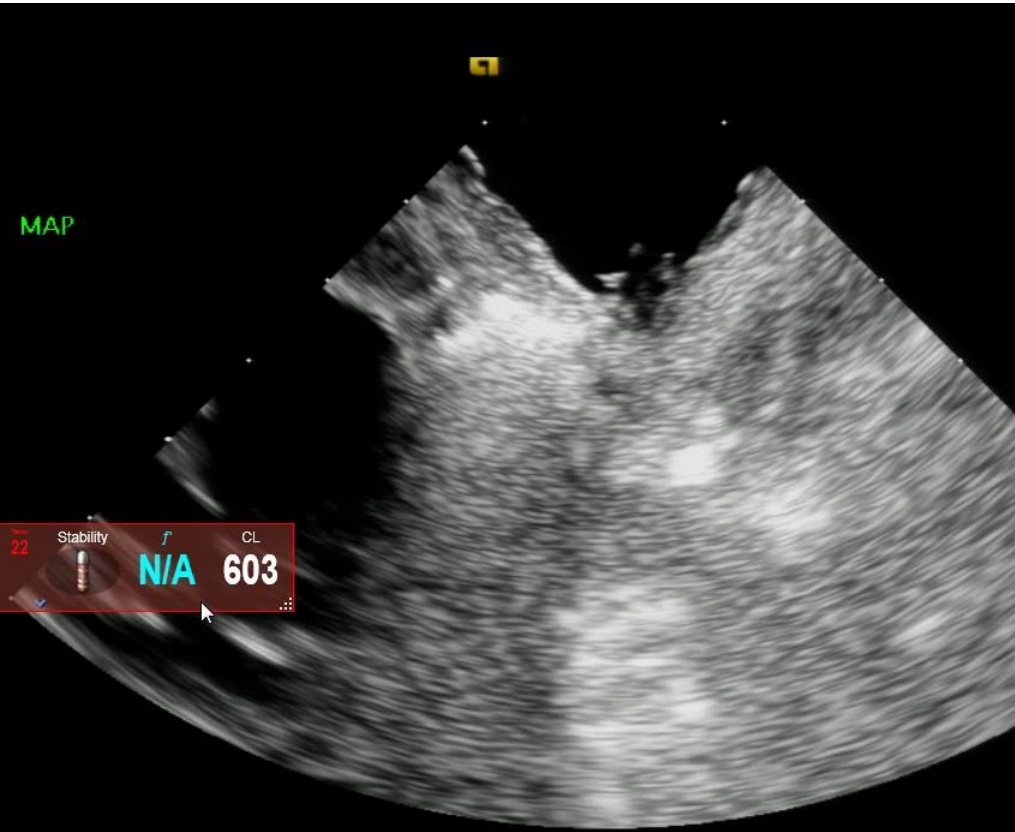
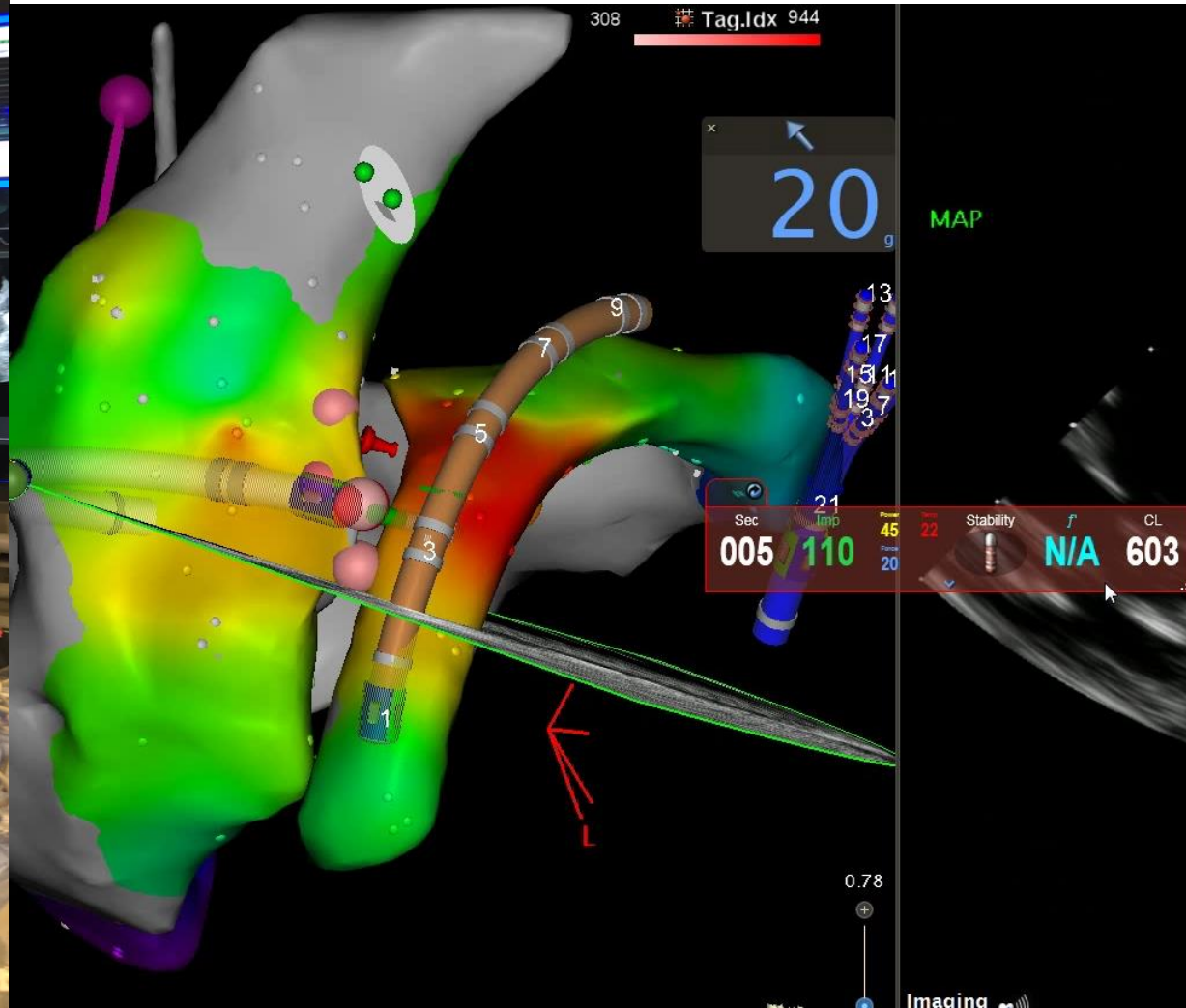
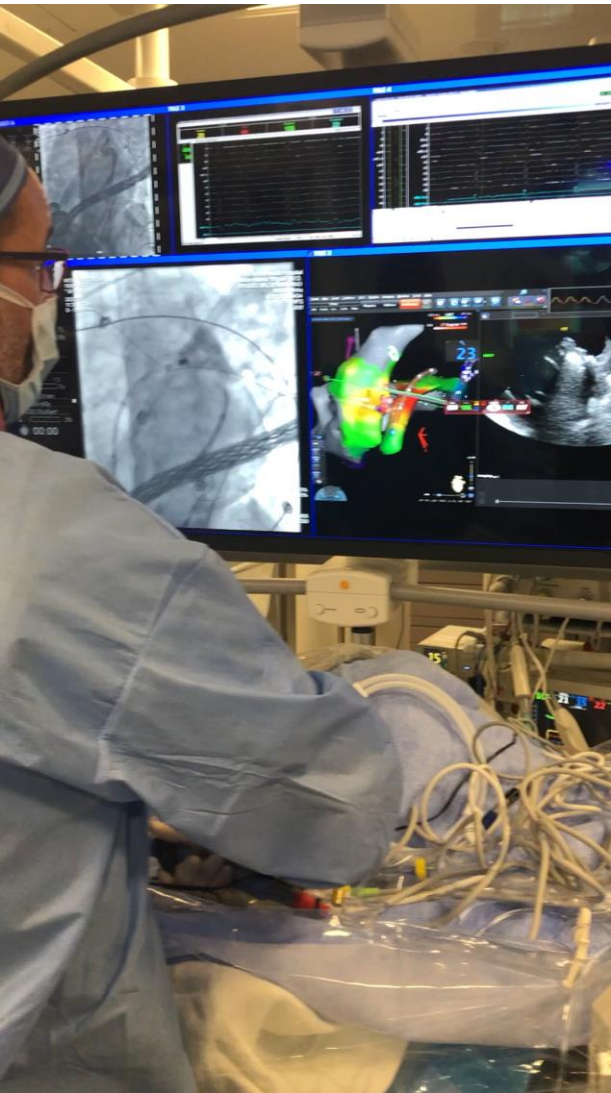
RBBB



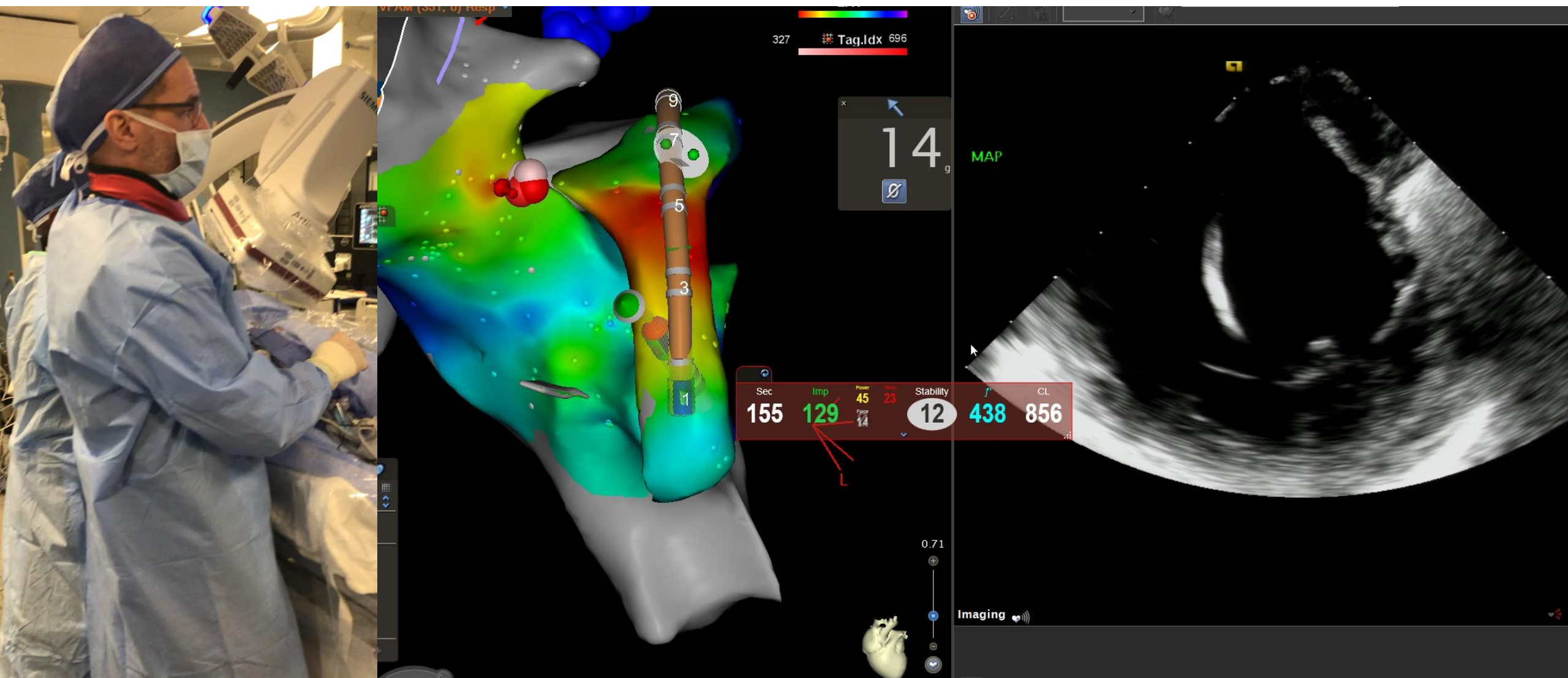RBBB resolved



Reinforced in RV and LV sides



Reinforced in RV and LV sides



24h CMR: myocardial edema, microvascular obstruction

